MICRO CLEAR

APOLLO RETINAL ATLAS

Ultra-wide Laser Scanning System
Confocal Retina Ophthalmoscope

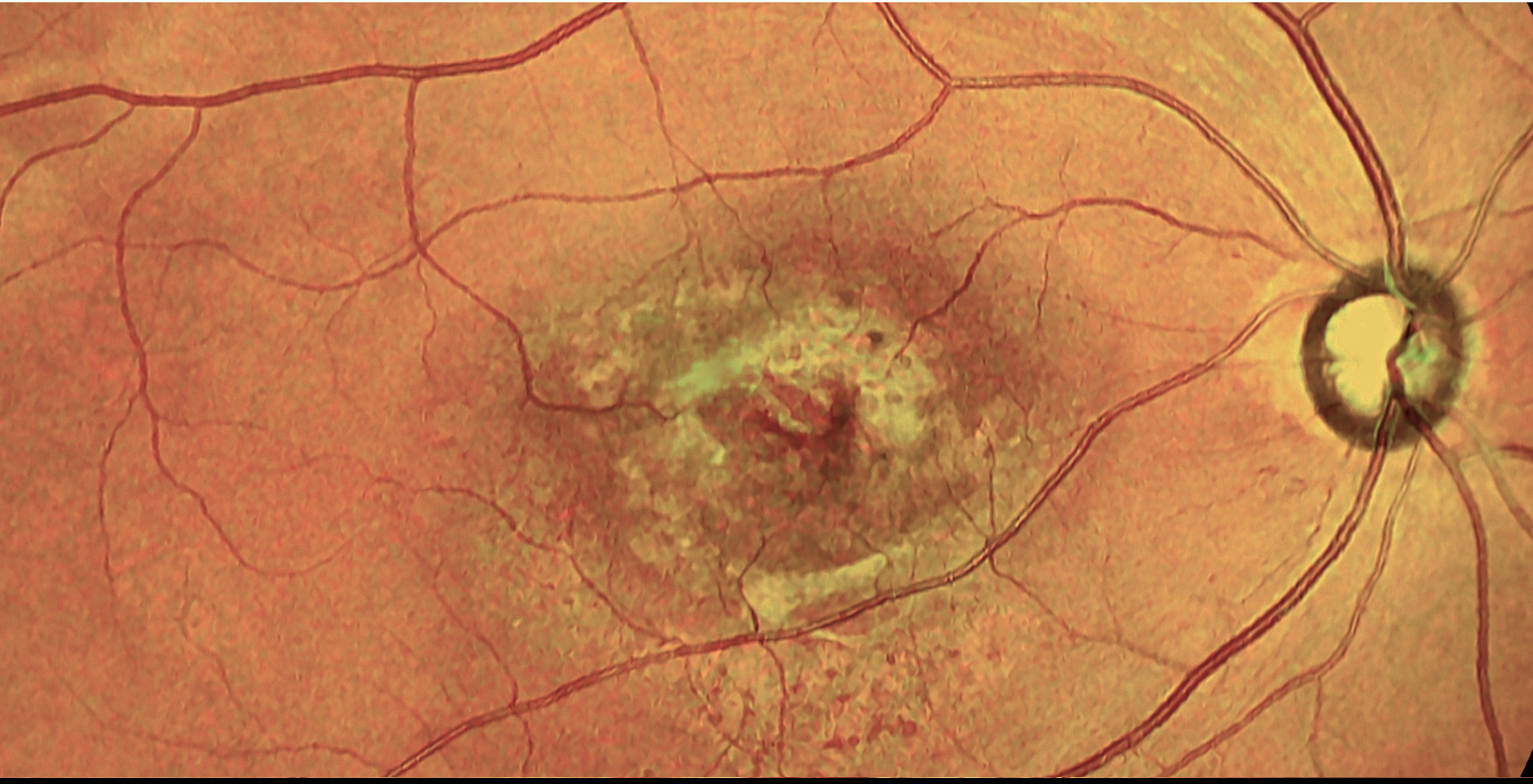

CASE COLLECTION OF MICROCLEAR APOLLO CONFOCAL LASER COLOR PHOTOS

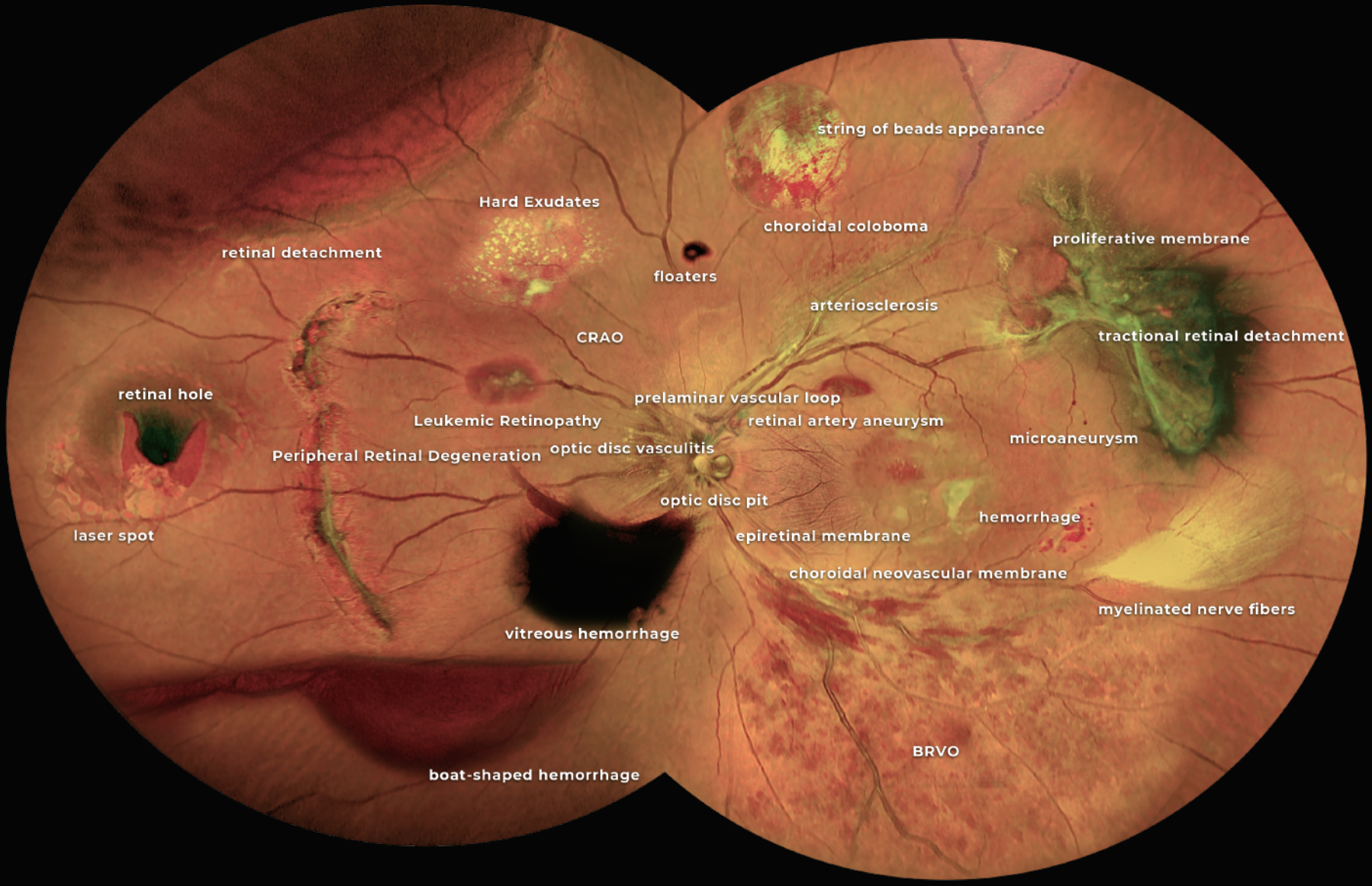

NORMAL FUNDUS STRUCTURE

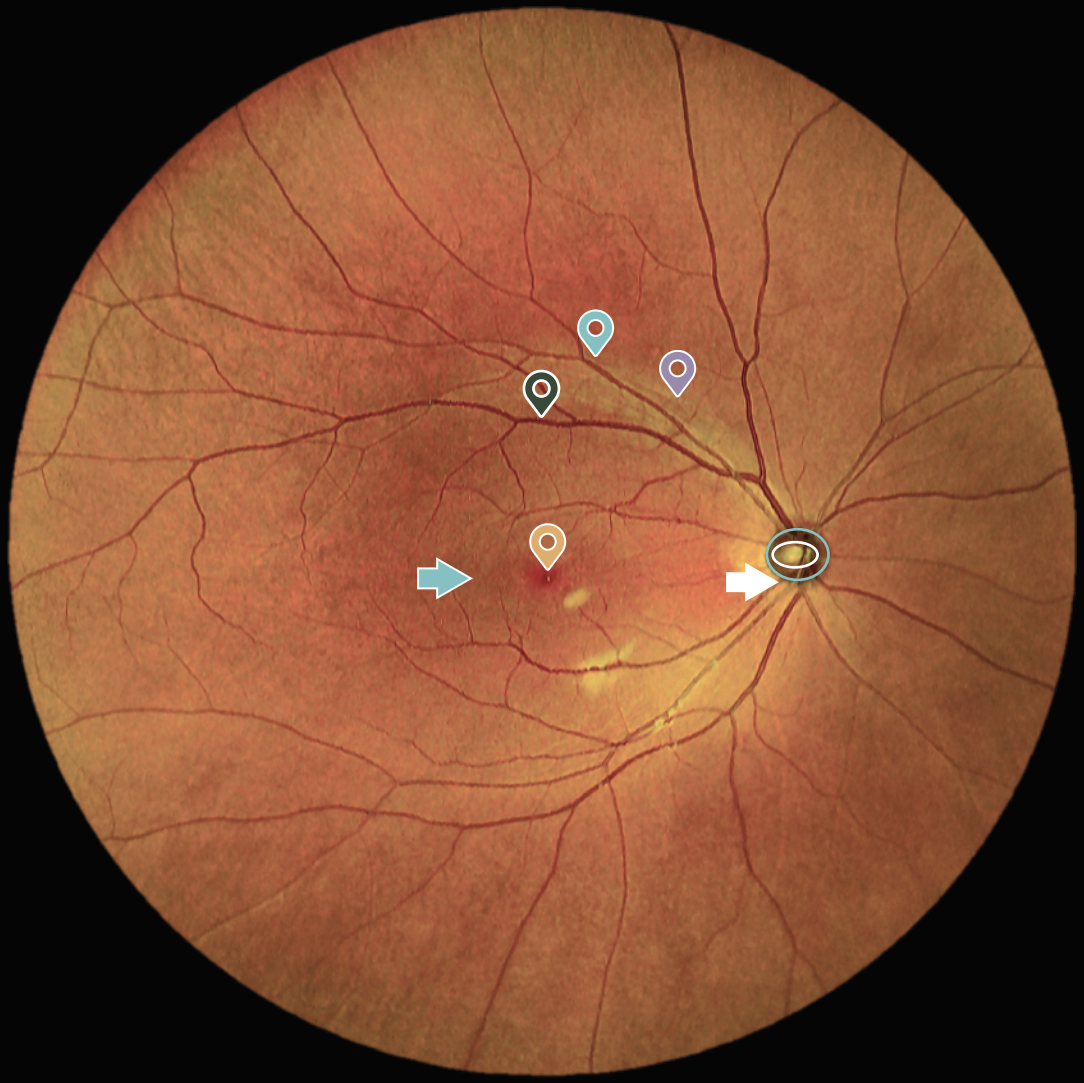

Vein
Send blood back to the heart

Artery
The vessels that bring blood to the heart

Nerve fiber layer

Optic cup

Optic disc

Macula
A small portion of the retina surrounds the fovea

Fovea
Most acute vision, no retinal blood vessels

Optic disc
The point on the retina where the optic nerve exits the eye, lacking light□sensitive cells and creating a blind spot.

A

RETINAL AND CHOROIDAL VASCULAR DISEASES

Diabetic retinopathy	1
Retinal macroaneurysm	5
Central retinal vein occlusion	7
Hemicentral retinal vein occlusion	9
Branch retinal vein occlusion	10
Branch macular vein occlusion	12
Central retinal artery occlusion	14
Branch retinal artery occlusion	15
Retinal precapillary arteriole occlusion	16
Systemic lupus erythematosus	17
Familial exudative vitreoretinopathy	18
Leukemic retinopathy	19

B

DEGENERATIVE AND NUTRITIONAL DISORDER-LIKE FUNDUS DISEASES

Age-related macular degeneration	20
Polypoid choroidal vasculopathy	22
Macular hole	24
Macular preretinal membrane	26

C

FUNDUS CONGENITAL ANOMALIES

Morning glory syndrome	28
Optic disc drusen	29
Congenital pre-optic disc vascular loop	30
Retinal myelinated nerve fibers	31
Congenital choroidal defect	32

CONTENTS

DIABETIC RETINOPATHY, DR

Diabetic retinopathy is one of the most common microvascular complications of diabetes and the most common clinical retinal vascular disease. The underlying pathophysiological process is the accumulation of various abnormal metabolites caused by hyperglycemia, resulting in damage and loss of retinal vascular pericytes and vascular endothelial cells, microvascular occlusion, and blood-retinal barrier damage, resulting in retinal exudation and edema, which seriously affects the Vision; followed by ischemia and hypoxia, abnormal neovascularization, exudation and hemorrhage of new blood vessels, causing traction retinal detachment, and eventually blindness.

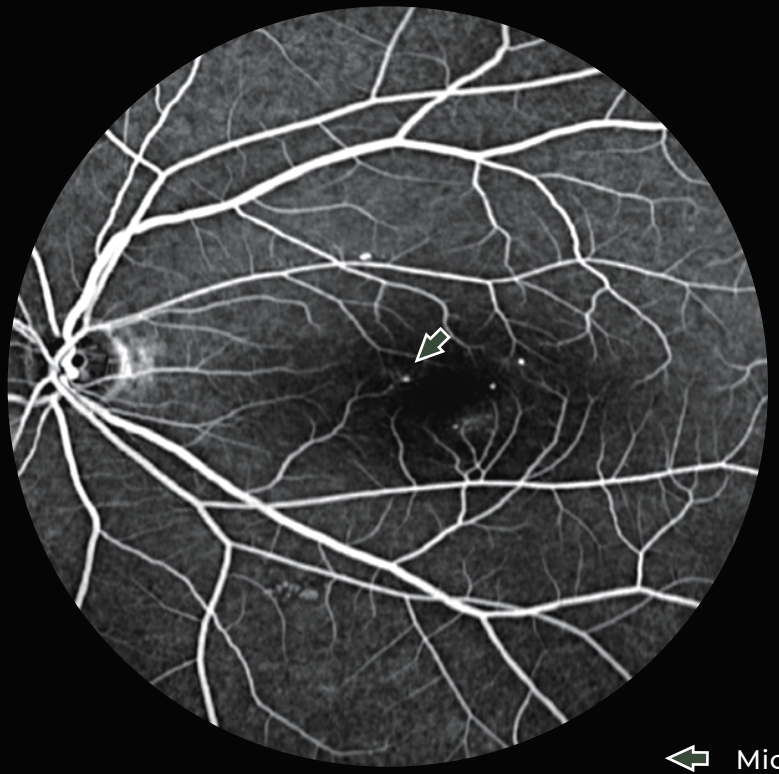

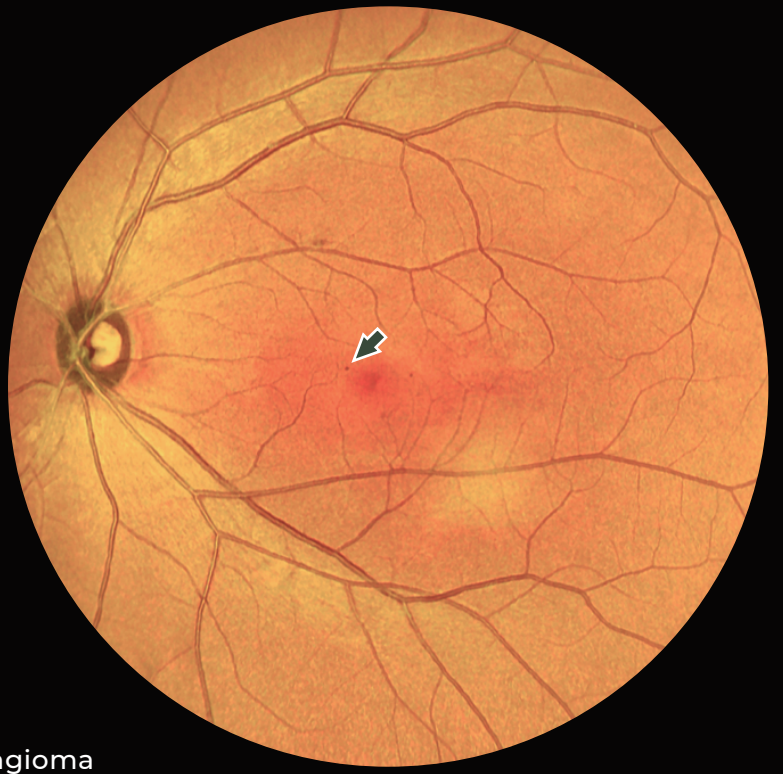

⇦ Microhemangioma

COLOR:

Flaming hemorrhage of the retina along the distribution of blocked veins, with yellowish-white cotton wool spots in between, and green macula suggesting macular edema.

DIABETIC RETINOPATHY

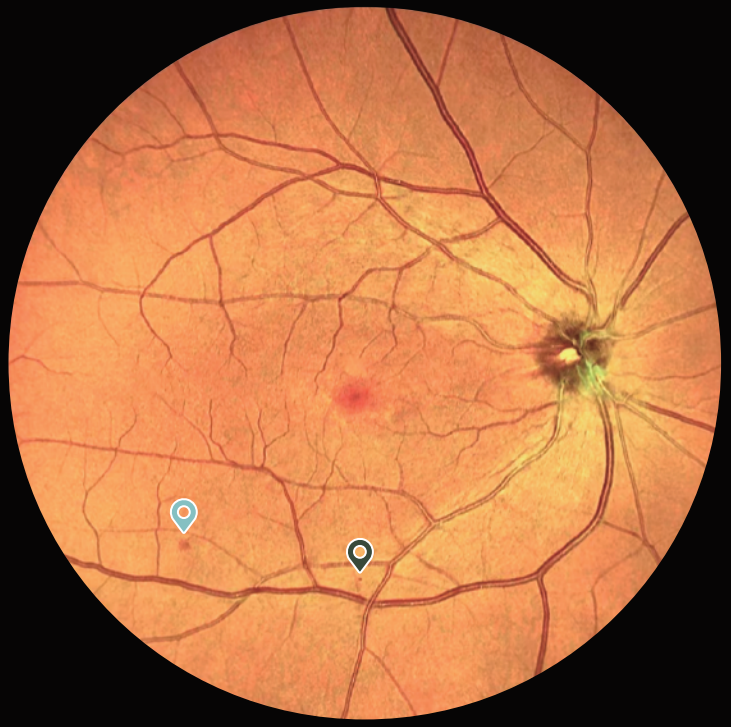

Dark red microhemangioma can be seen near the vascular arch below the macular area, and hemorrhagic spot can be seen below the temporal area.

Hemorrhagic spot Microhemangioma

Dark red microhemangioma, hemorrhage spots, and yellowish-white hard exudates can be seen in the macular area.

Hemorrhage Hard exudate

Microhemangioma

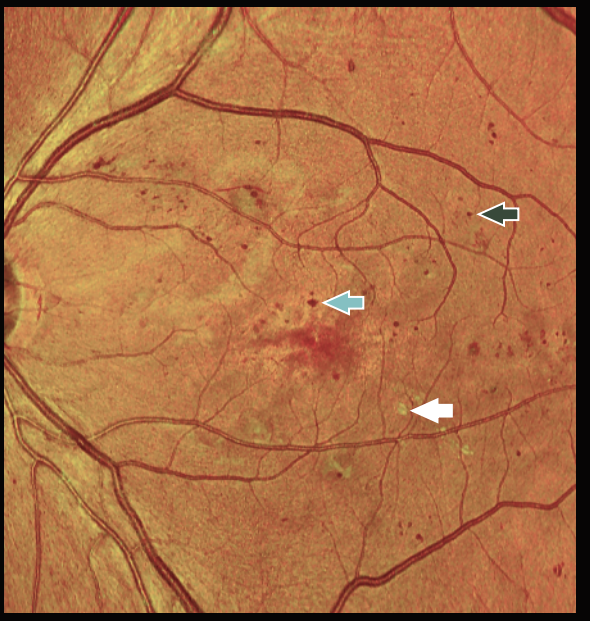

DIABETIC RETINOPATHY

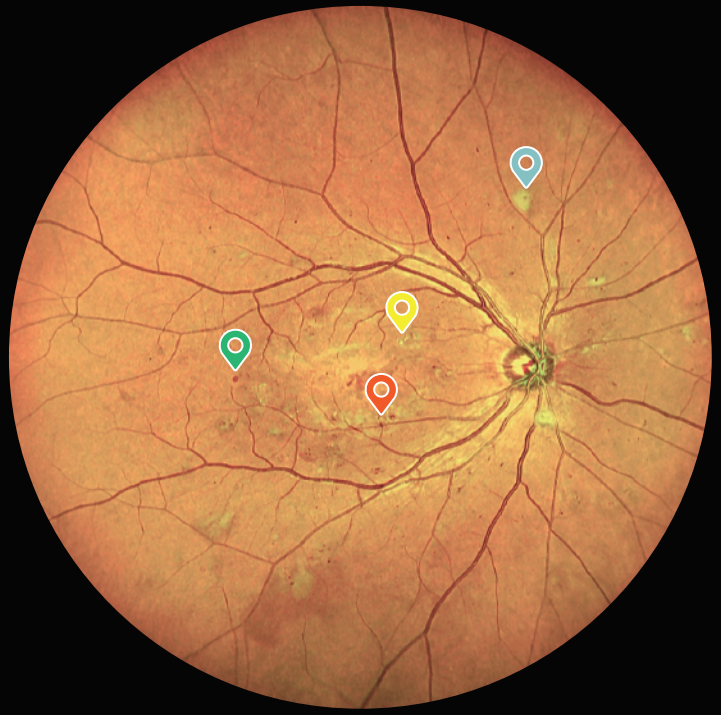

Sheet hemorrhages, numerous microangiomas, hard exudates with clear boundaries, and cotton wool spots can be seen in the posterior pole.

- Cotton wool spot
- Hard exudate
- Microhemangioma
- Hemorrhage

Retinal spot hemorrhages,groups of yellowish-white cotton wool spots with retinal visible near the cotton wool spots.Abnormal IRMA of internal microvascular (red arrow).

- IRMA
- Cotton wool spot
- Sheet hemorrhage

DIABETIC RETINOPATHY

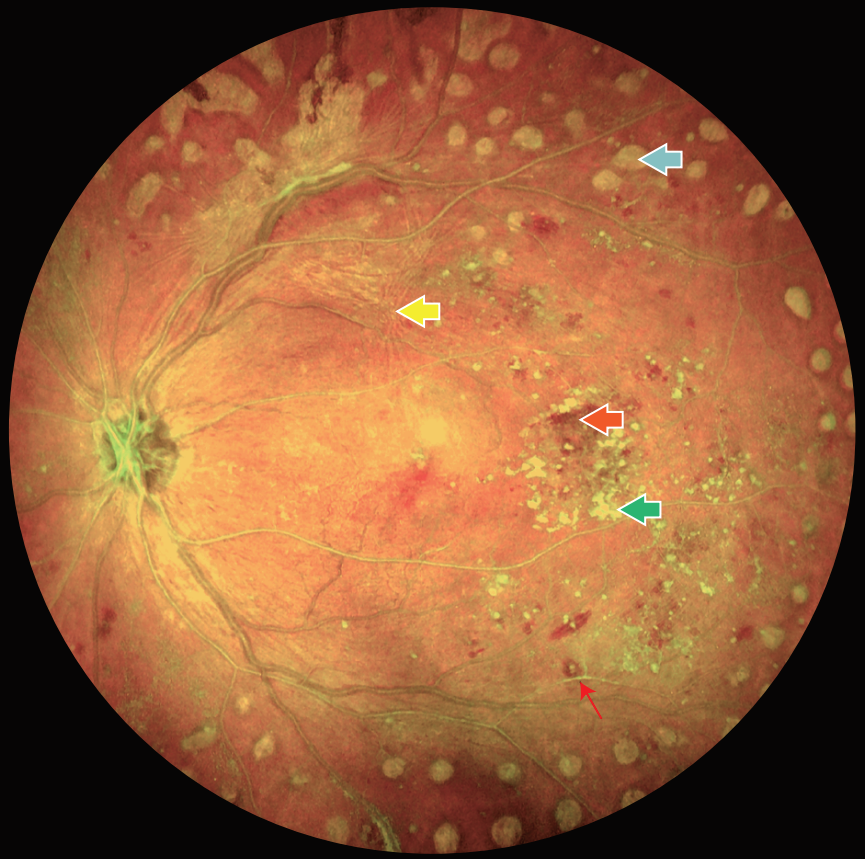

The retina shows many hard exudates, Sheet hemorrhage, central white point retinal hemorrhage Roth's spot (red arrow)

- Laser spot
- Epiretinal membrane
- Hemorrhage
- Hard exudate

RETINAL MACROANEURYSM

Retinal macroaneurysm, also known as acquired large retinal aneurysm, is a common ocular fundus disease in the elderly, mostly in women (70%). It is characterized by limited dilatation of one or more retinal artery walls in the fundus, which is cystic. Diverticuloid or fusiform, mostly located before the third branch of the retinal artery. Most of the patients were monocular and 10% were bilateral. Most patients with hypertension. Arteriosclerosis, hyperlipidemia and other physical conditions related. Its clinical manifestations are diverse, and it is often misdiagnosed as other fundus diseases, such as exudative age-related macular degeneration, branch retinal vein obstruction, etc.

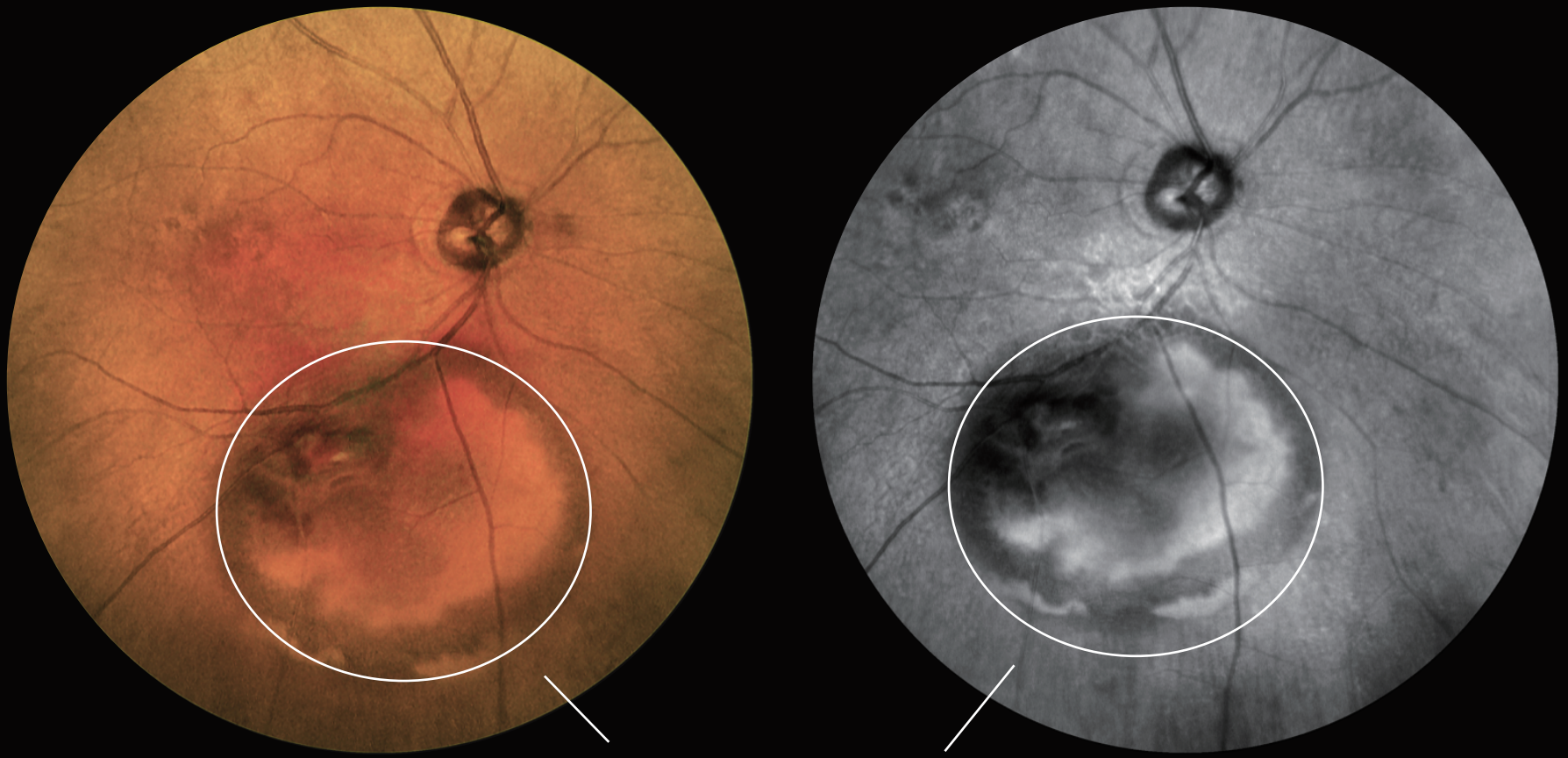

Retinal macroaneurysm

FFA examination showed that the fluorescence filling of the affected artery was normal or slightly delayed. In the aneurysms with less bleeding, tumor development was observed immediately within the arterial period, and the tumor showed spherical and/or fusiform strong fluorescence. In the later stage, there were different degrees of fluorescence leakage and staining of the tumor wall, and the bleeding around the tumor showed weak fluorescence and obscured the fluorescence of the choroid. Periarterial capillary dilatation and leakage, microaneurysm formation were also observed. Around the aneurysm, there is no widening of the capillary area around the artery, and there may be a small non-perfusion area nearby. Macular yellow lipidosis, unless particularly dense, usually does not block fluorescence.

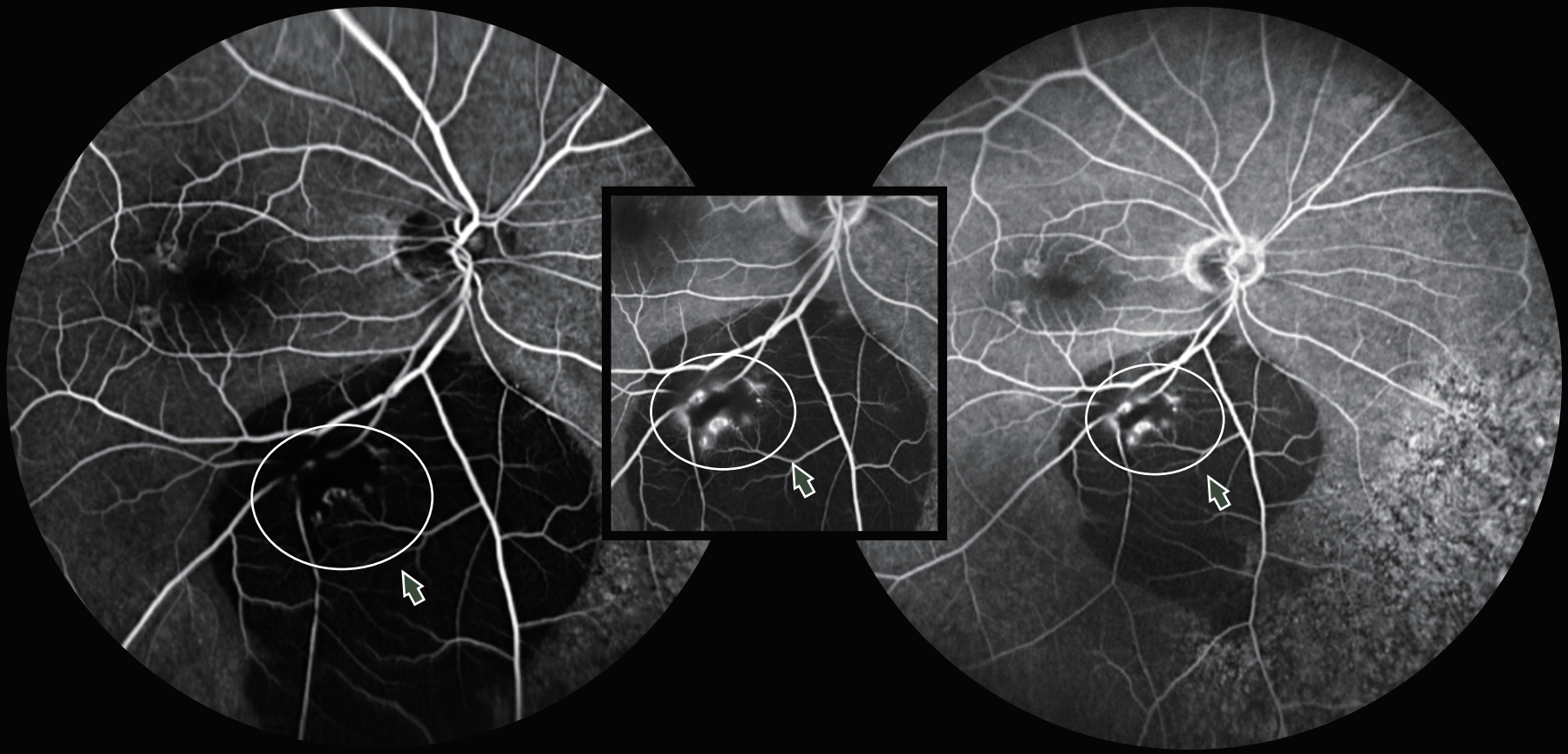

⇦ Retinal macroaneurysm

CENTRAL RETINAL VEIN OCCLUSION, CRVO

Central retinal vein occlusion (CRVO) is an obstruction that occurs in the trunk of the retinal veins. The pathogenesis of this disease is not very clear, it is currently considered to be central retinal vein thrombosis at or behind the cribriform plate. Painless sudden loss of vision is the main reason for this disease to see a doctor. The degree of vision loss depends on the degree of venous occlusion and the amount of macular hemorrhage. In severe cases, vision can be reduced to digital or manual vision, but there are also mild vision loss or even no vision loss. Hemi-venous obstruction also belongs to this type.

COLOR:

Retinal veins are tortuous and dilated, with radially distributed patchy hemorrhages;

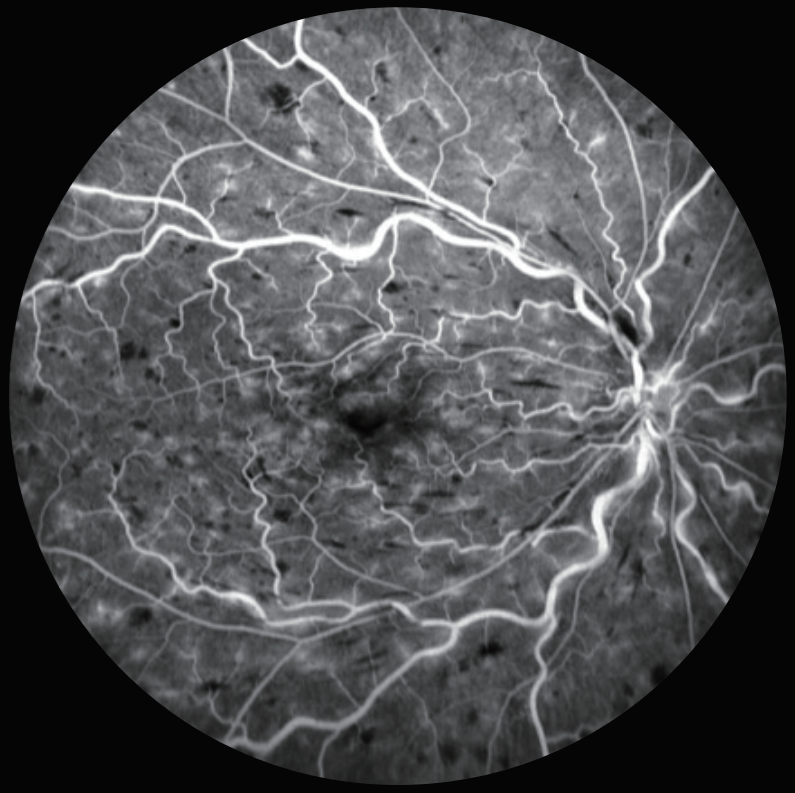

FFA:

Shows tortuous and dilated retinal veins, fluorescent staining and leakage, hemorrhage covering fluorescence, and macular edema.;

XCENTRAL RETINAL VEIN OCCLUSION, CRVO

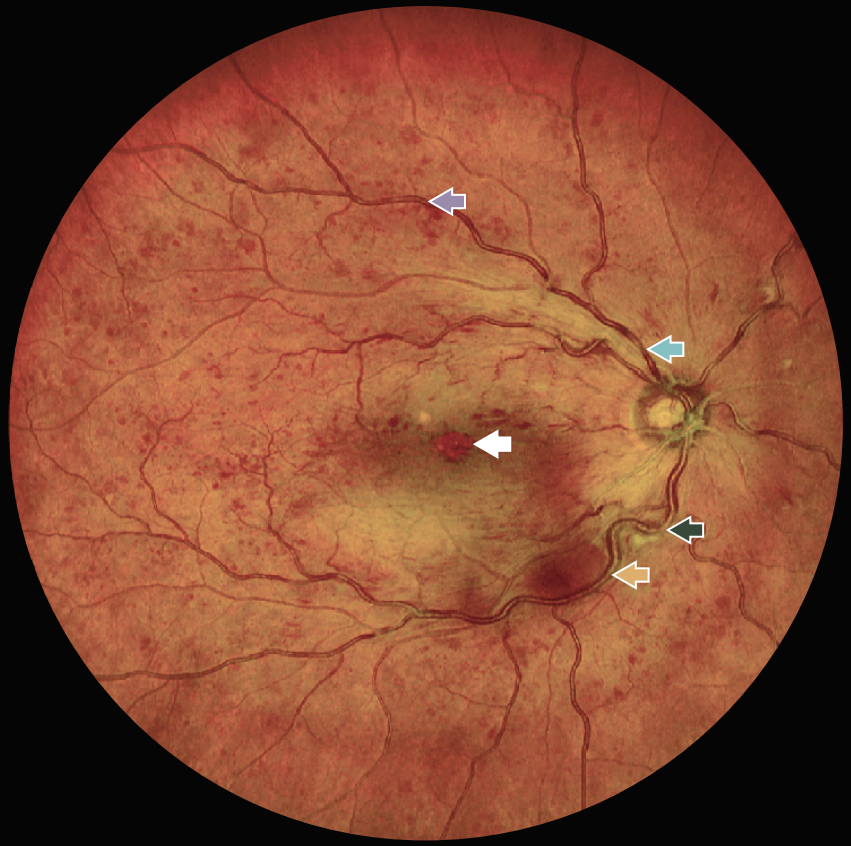

- Hemorrhage
- Blood vessels are nodular
- "Cystoid edema"
- Cotton wool spots
- Vascular tortuosity, dilation

- Hemorrhage
- Dilated, "nodular" blood vessels
- “Flaming" superficial hemorrhage
- Optic disc hyperemia and mild swelling, hyperemia, blurred border
- Macular edema

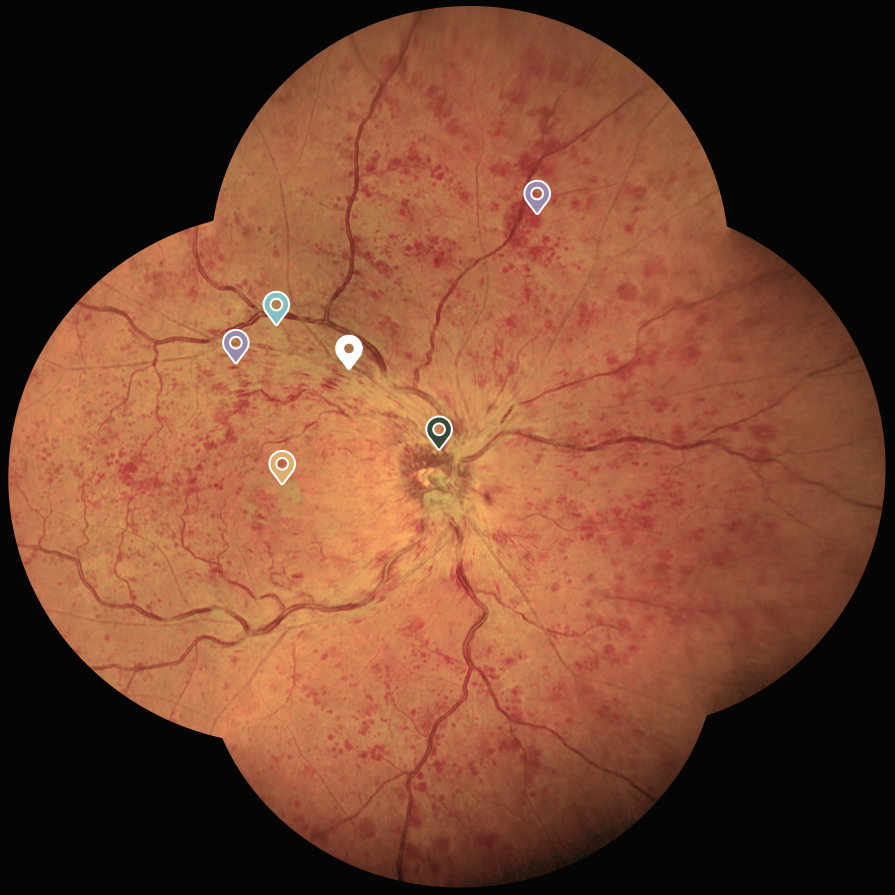

HEMICENTRAL RETINAL VEIN OCCLUSION

In cases of hemicentral retinal vein occlusion, two primary central veins are present on the optic disc, but one of them is occluded. This condition is relatively rare in clinical practice. Typically, only one trunk of retinal veins is observed on the optic disc. However, due to developmental variations, a small number of individuals may have two or even three trunks of veins on the optic disc. When one of the main trunks becomes blocked, either at the cribriform plate or within the optic nerve, it leads to specific retinopathy in the half of the fundus drained by the occluded vein, with the extent of the affected area depending on the degree of drainage. This area can encompass one-third or two-thirds of the overall fundus.

The clinical manifestations of hemicentral retinal vein occlusion vary based on which main vein is involved. These may include retinal hemorrhage, edema, exudation, tortuous and dilated veins, and a dark purple appearance in the drainage area of the vein. Vein occlusion can affect different trunks, resulting in varying degrees of retinal involvement. As the disease progresses, hemorrhages and edema resolve, the retinal vein ceases to expand tortuously, and white sheaths parallel to the blood vessels may form along its diameter. Additionally, irregular, distorted retinal neovascularization and collateral circulation formation can also become visible.

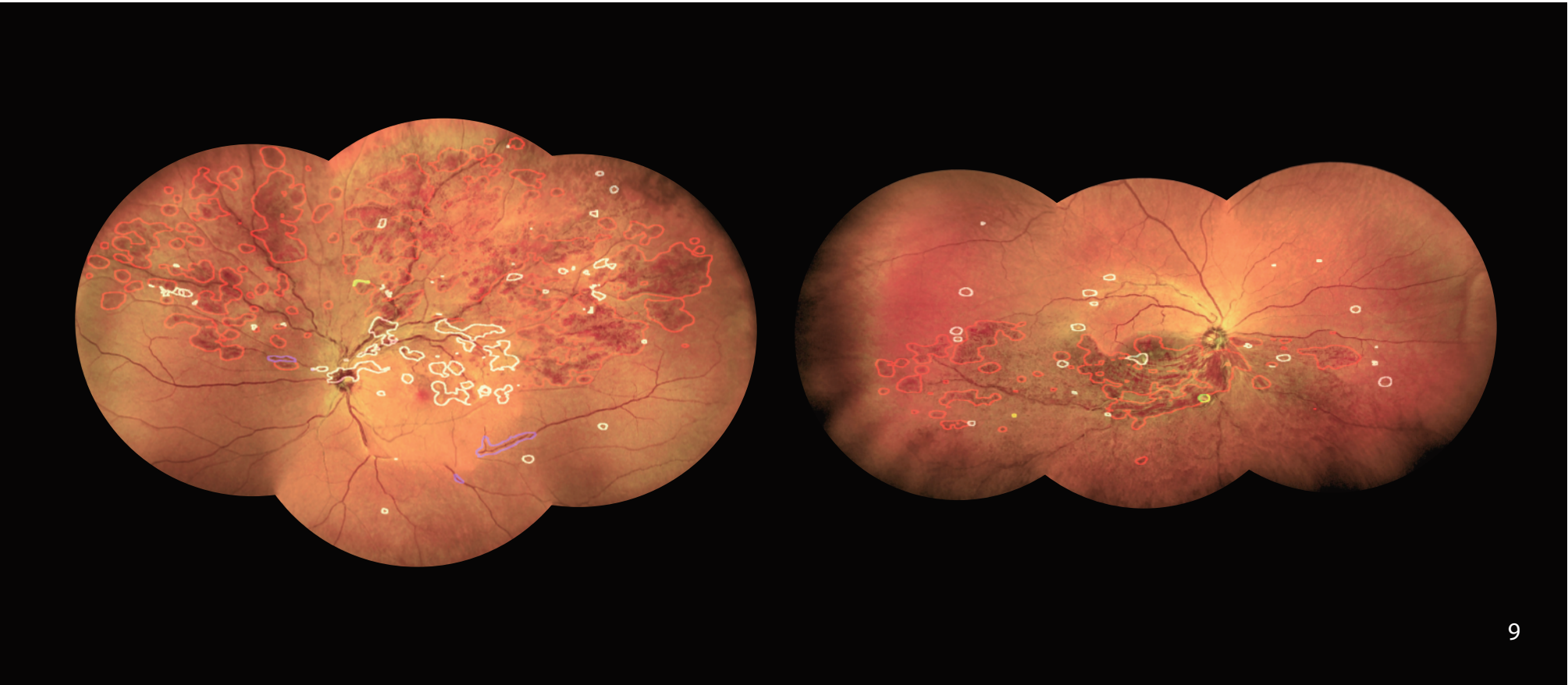

BRANCH RETINAL VEIN OCCLUSION, BRVO

This occurs with vein occlusion of a branch of the retinal vein. This disease is more common in patients with arteriosclerosis, and the obstruction site is often located at the arteriovenous intersection from the first branch of the vein to the third branch, and the artery is mostly located in front of the vein; it is also seen in small branch obstruction, such as obstruction of the branch to the macula. After the onset, the vision is mostly affected by the location and scope of the vein blockage, accompanied by visual field defect or black shadow blocking feeling corresponding to the blockage area.

- Cotton wool spots
- Edema
- Vascular occlusion
- Hemorrhage

Flaming hemorrhage of the retina along the distribution of blocked veins, with yellowish-white cotton wool spots in between, and green macula suggesting macular edema.

BRANCH RETINAL VEIN OCCLUSION, BRVO

- Laser spot
- Vascular occlusion
- Cotton wool spots
- Hard exudate
- Hemorrhage

BRANCH MACULAR VEIN OCCLUSION

Retinal vein occlusion only involves a small vein draining the macula, which is called macular branch vein occlusion. Since the lesion is adjacent to or has involved the fovea, although the lesion is not large, vision can be affected to varying degrees, so special attention should be paid.

Edema, hemorrhage, and peripheral annular exudates in the macular area. In the early stage of occlusion, the permeability of the venous wall increases, and the blocked branch venules are very small, which are often blocked by retinal hemorrhage. And because it is located in the macula, the retinal edema is serious, and it is not easy to be found. After several months of occlusion, the retinal hemorrhage is absorbed, but the retinal tissue can be chronically edematous, degenerated, and even shrunk and thinned.

FFA examination shows uneven caliber of blocked venules, staining of vessel wall, no perfusion of nearby capillaries, peripheral telangiectasia, microangioma, late leakage.

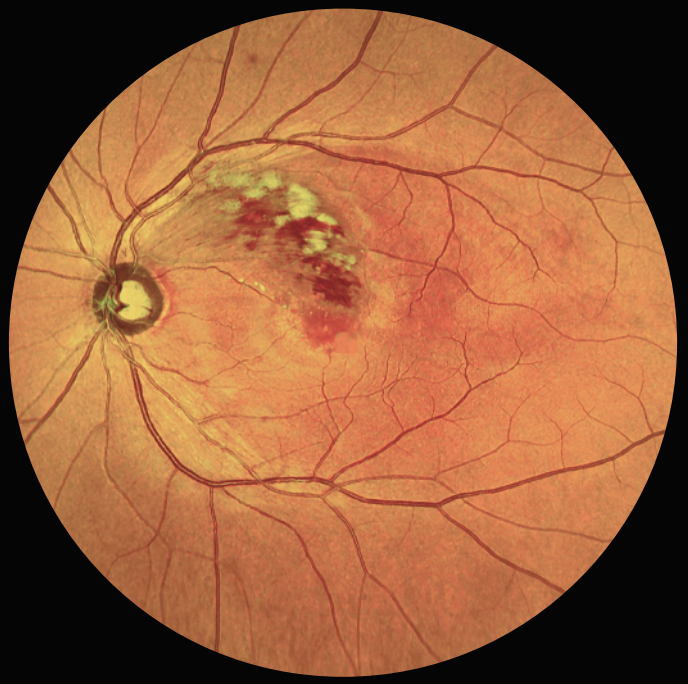

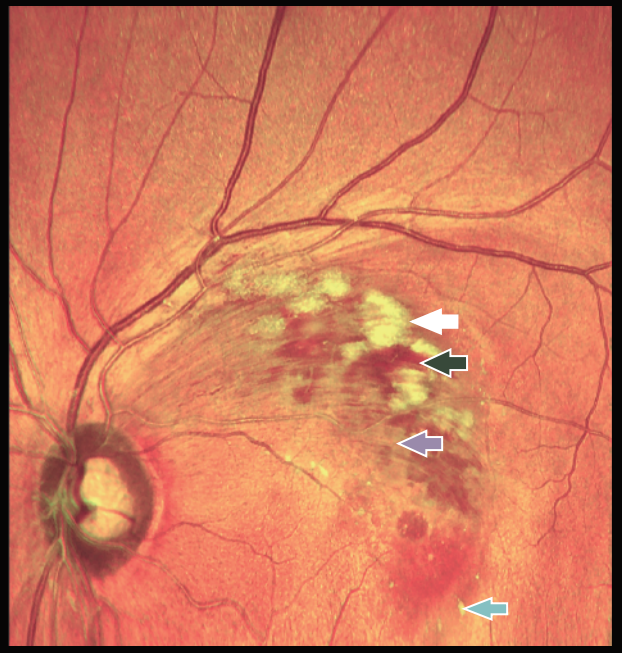

Cotton wool spots

Hemorrhage

Edema

Exudate

BRANCH MACULAR VEIN OCCLUSION

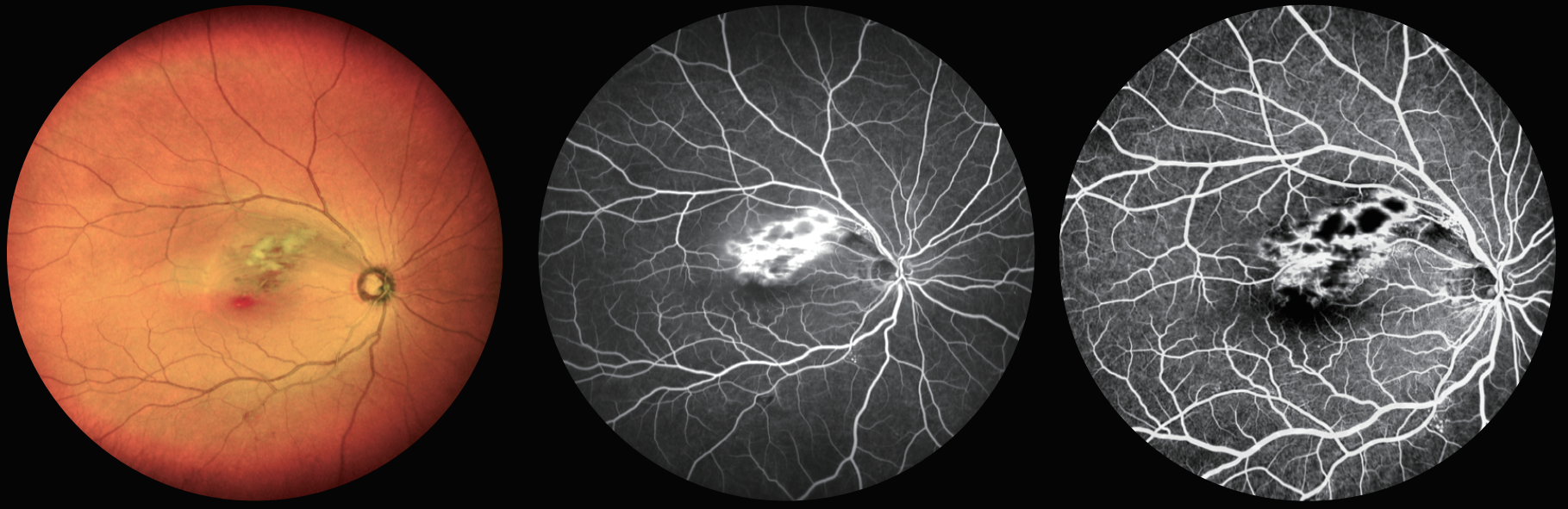

COLOR:

Macular superior temporal branch vein occlusion, radial hemorrhage and yellow-white cotton wool spots can be seen;

FFA:

Fluorescence leakage in the blocked area, Fluorescence obscured by hemorrhage and cotton wool spots, integrity of macular arch ring damaged, supramacular edema.

CENTRAL RETINAL ARTERY OCCLUSION, CRAO

CRAO is characterized by sudden painless vision loss due to occlusion of the central retinal artery. This disease is common in arteriosclerosis. In patients with hypertension, it is caused by various types of emboli or thrombus from other sites or in situ. The sieve plate is the most common site of central retinal artery occlusion. It can also be secondary to intraocular surgery of sudden increase in intraocular pressure, retinal artery compression; Or arterial spasm as a direct result of surgical injury/irritation.

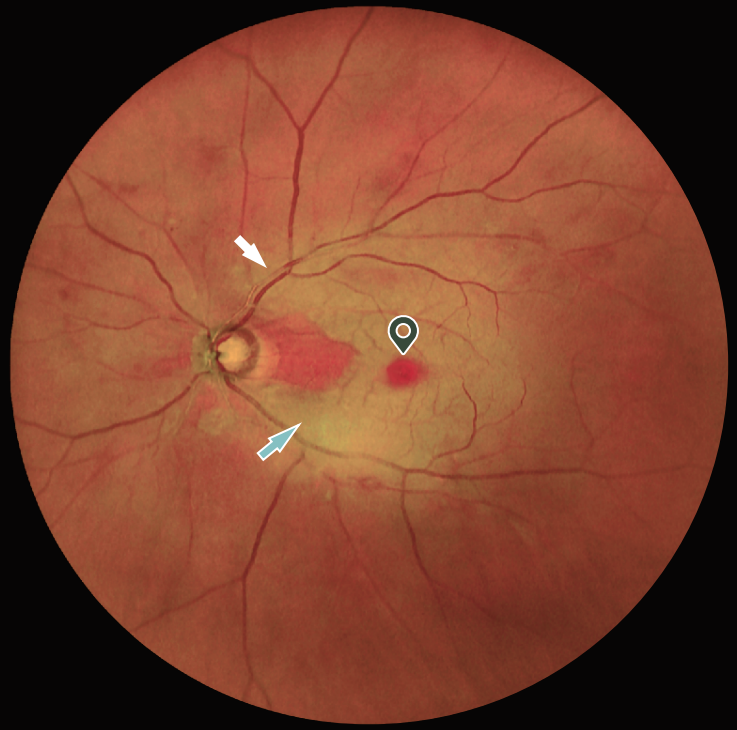

The yellow green area is the retina edema area, the edge is clearly visible

Segmentation of the blood column due to stagnation of blood flow and aggregation of red blood cells Both arteries and veins have this phenomenon, especially veins

“Cherry Red Spot”

Apollo fundus images ← optical contrast → competitors images quality

COLOR:

The arteries are thinner, the retina at the posterior pole is yellow-green edema, and the macula is "cherry red". About 25% of acute CRAO eyes have one or more ciliary retinal arteries supplying part or the whole mammary tract, and the retina in the blood supply area shows a tongue-shaped orange-red area.

BRANCH RETINAL ARTERY OCCLUSION

Occlusion that occurs in a branch retinal artery is called branch retinal artery occlusion (BRAO). The severity of vision loss therefore varies depending on where the occlusion occurs. Occlusion caused by various types of emboli or thrombus is the main cause of branch arterial occlusion.

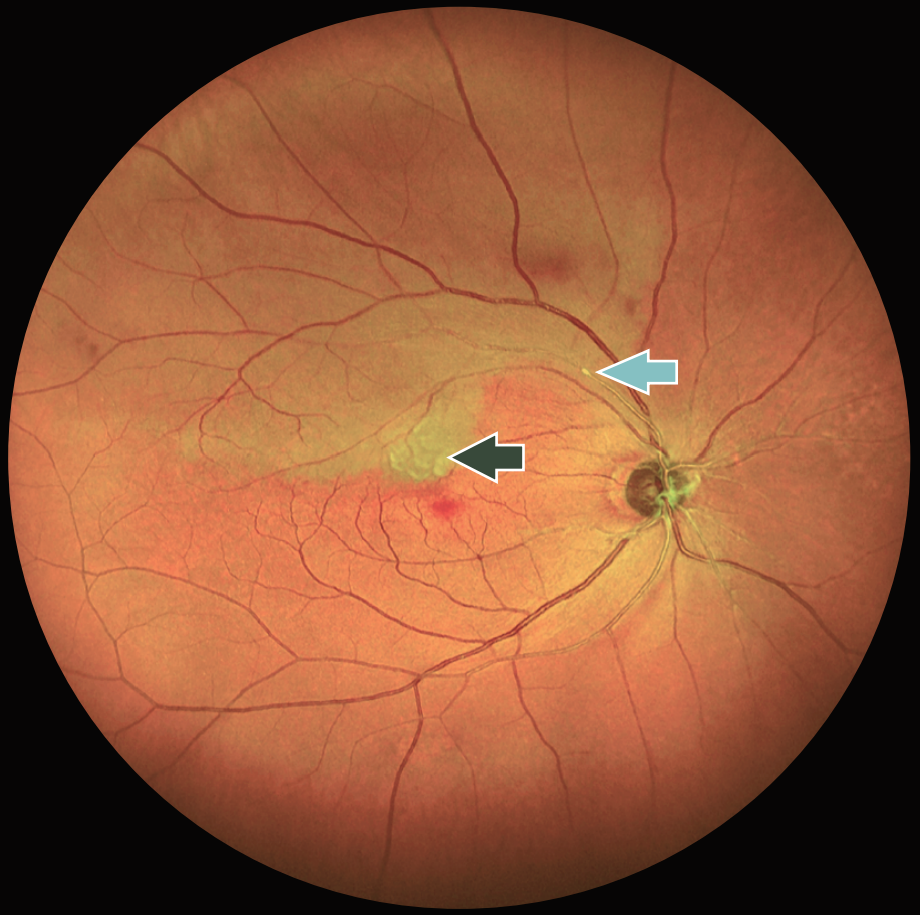

Retinal edema in the area of blocked arterial supply is yellow-green, and yellow-white emboli can be seen in the supratemporal artery of the optic disc.

Visible "yellow-white" emboli in arteries

Areas of retinal edema appear greenish-yellow

RETINAL PRECAPILLARY ARTERIOLE OCCLUSION

The fundus manifestations of multiple systemic diseases, such as hypertension, diabetes, collagen vascular disease, severe anemia, leukemia and subacute endocarditis, are also seen in traumatic retinochoroidopathy..

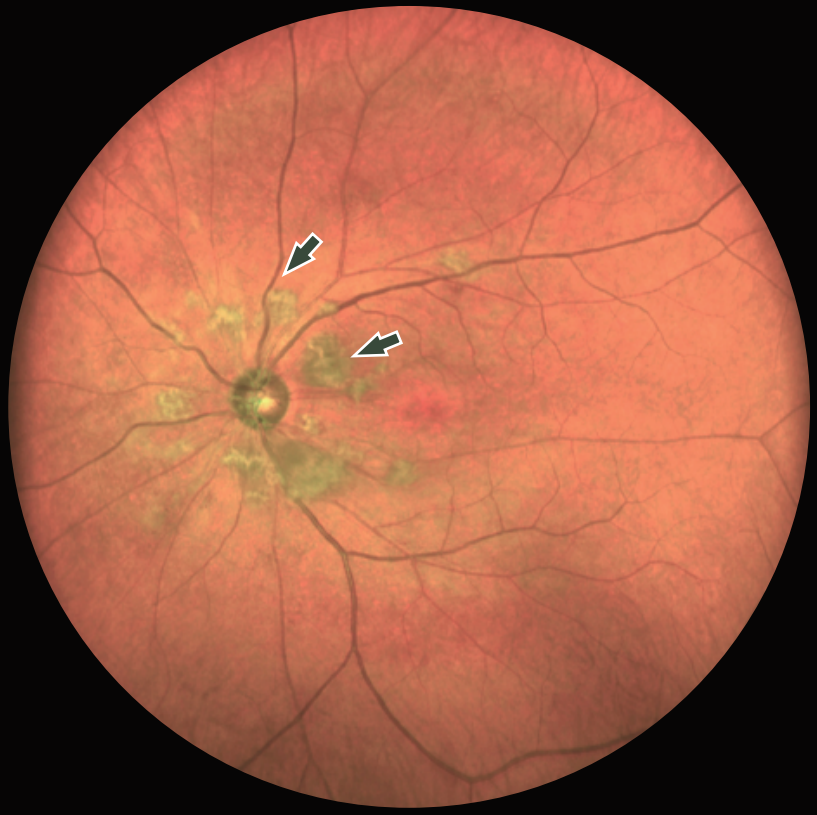

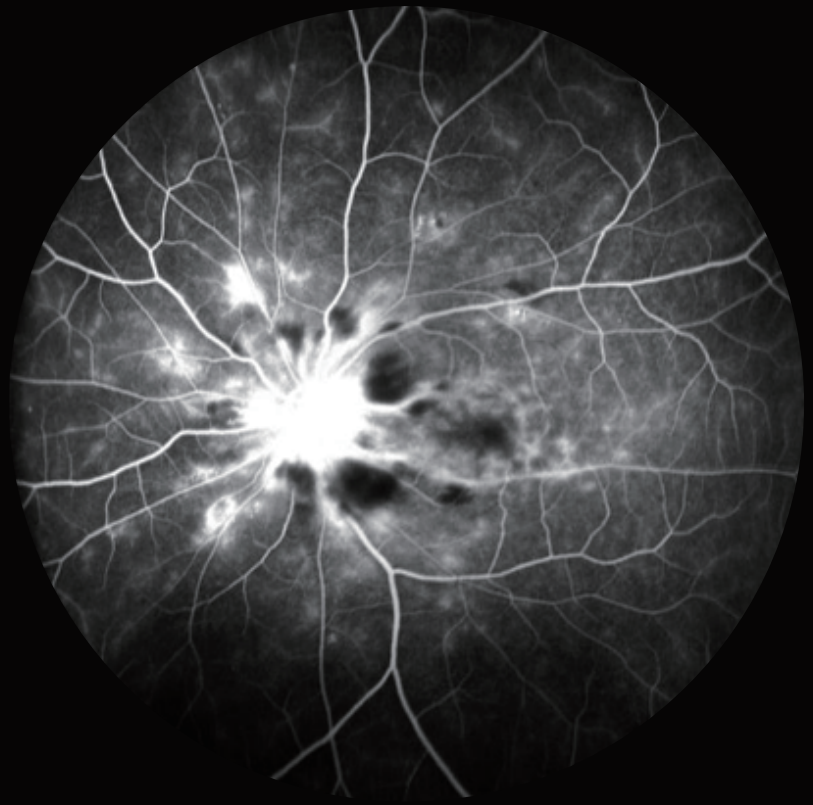

COLOR:

Yellow-green flakes of opacity appear in the retina at the occlusion , which are cotton wool spots

⇦ Cotton velvet spots due to Retinal precapillary arteriole occlusion, located on the surface of the retina, usually less than 1/4 of the optic disc

FFA:

The optic disc showed high fluorescence, multiple patches of high fluorescence can be seen around the optic disc, multiple low fluorescence can be seen beside the optic disc, multiple peripheral vascular wall staining, macular edema.

SYSTEMIC LUPUS ERYTHEMATOSUS, SLE

Systemic lupus erythematosus is an autoimmune disease involving multiple systems and organs. The degree of fundus damage is closely related to the progression of SLE. Fundus changes occur in 20% to 25% of patients, the most common of which is retinal vascular damage in SLE patients.

Fundus examination findings: changes in the fundus may include blurred optic disc edges, mild edema, retinal exudation and hemorrhage, especially in the acute stage, when a butterfly-shaped rash appears, cotton wool spots or Foggy patches. There are yellow and white dots or small round white bumps in the macula. When the general symptoms are relieved, the cotton wool spots can disappear, and sometimes atrophic spots can be left. Retinal hemorrhage and vitreous hemorrhage occasionally occurred. The distribution of bleeding varies, and it can be distributed along blood vessels and exudates, or it can have nothing to do with blood vessels. The manifestations of retinal vascular lesions are also different. There may be venous dilatation, filling, periarteritis, obliterative arteritis, periphlebitis, and white lines formed by vascular fibrosis and venous obstruction, mainly in peripheral blood vessels. In advanced disease, optic disc edema involves the surrounding retina, eventually leading to primary or secondary optic atrophy.

Cotton wool spot

Hemorrhage

Beading changes

FAMILIAL EXUDATIVE VITREORETINOPATHY, FEVR

Familial exudative vitreoretinopathy is an inherited disease of abnormal retinal vascular development.Typical manifestations of FEVR are peripheral retinal capillary non-perfusion, peripheral fibrovascular proliferation and traction retinal detachment, and subretinal exudation or exudative detachment may occur. Some patients have a long period of quiescence, which may be combined with high myopia, macular ectopia, and small retinal vessel angles at the posterior pole. Retinal tears and rhegmatogenous retinal detachment occur in adolescence or adulthood. Most of them are bilateral, but the degree can be asymmetrical, so the inspection of "healthy eyes" cannot be ignored. FEVR often has a relatively long development process, even after treatment, there are still some patients whose condition tends to be active, so a long period of time or even life-long follow-up is required

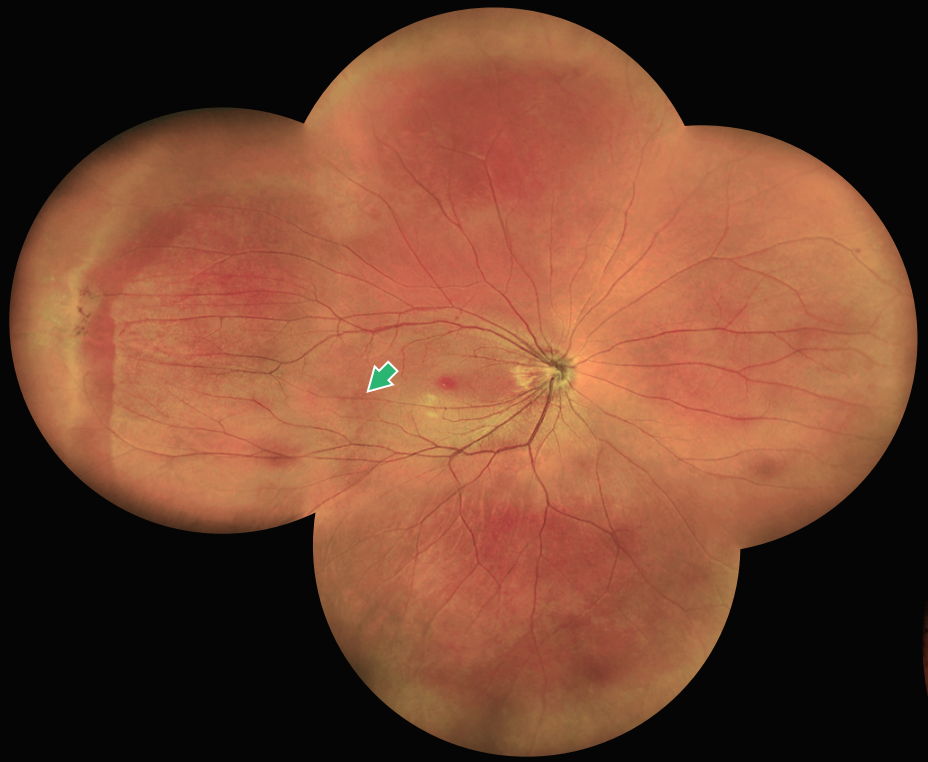

The retinal vessels at the posterior pole are traction-shaped, and the branch vessels of the upper and lower vascular arches form a V-shaped area

Laser spot

Anvascular region

LEUKEMIC RETINOPATHY

Typical features of leukemic retinopathy include retinal vein filling, dilation, tortuosity, and retinal hemorrhage. Changes in the retinal veins are the earliest obvious signs. The veins become tortuous and dilated, with an enlarged diameter. In the early stages, the arteries do not change significantly but may also expand in the later stages.Retinal hemorrhages can be found in both the superficial and deep layers, taking various shapes such as flames, spots, or specks. Most of these hemorrhages are located in the peripheral regions of the fundus. A distinctive type of hemorrhage is referred to as a "Roth spot," characterized by a white core in the center, believed to be associated with the aggregation of leukocytes, fibroblasts, and platelets.In leukemic retinopathy, the flow of blood in veins and capillaries is slow, resulting in retinal edema, thickening, and an orange or yellowish-white appearance. Star-shaped changes indicative of hard exudates can be observed in the macular area. Local small blood vessels may be occluded, leading to the formation of cotton wool spots.The severity of optic disc edema varies and is often related to local leukemic cell infiltration within the optic disc or intracranial leukemic cell infiltration causing elevated intracranial pressure.

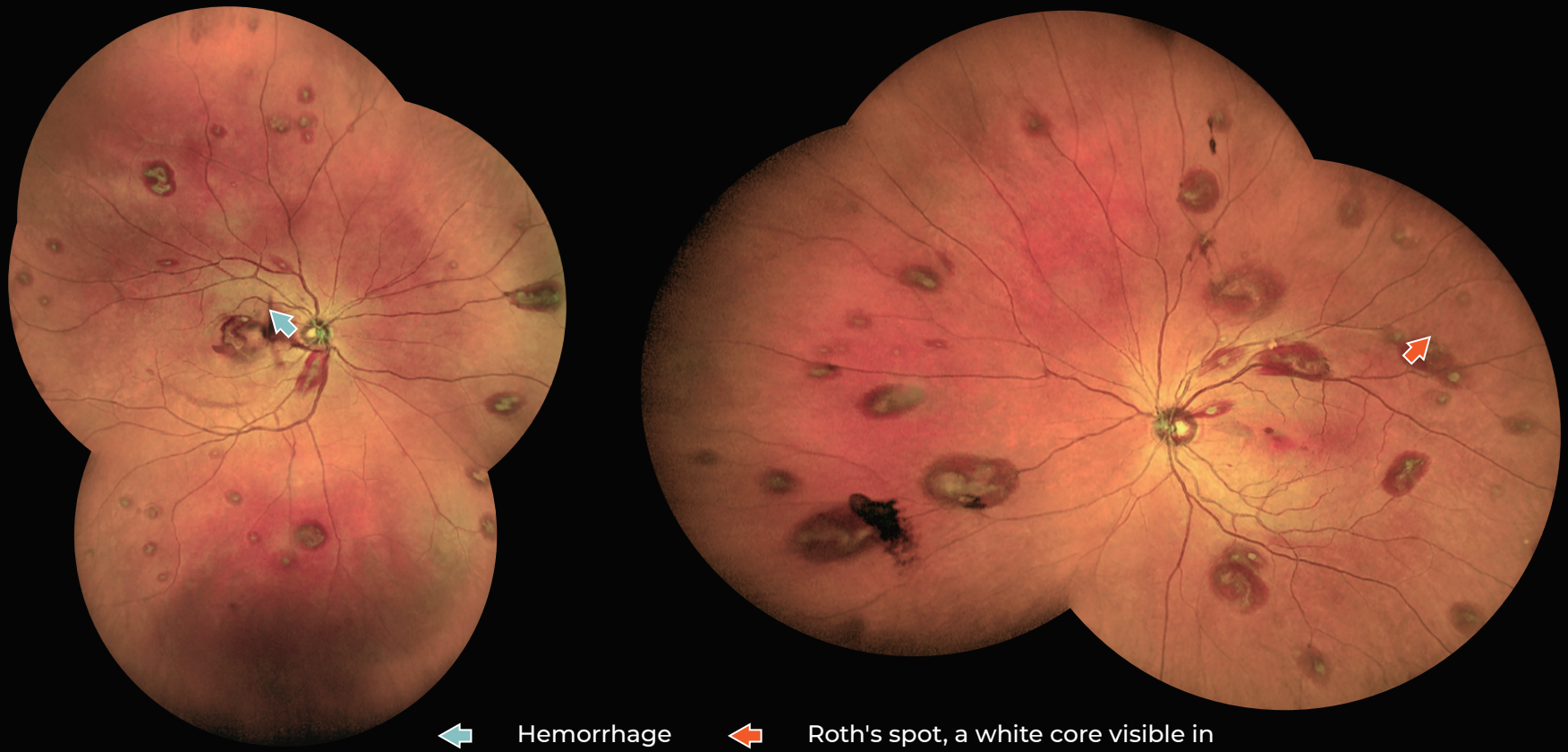

Hemorrhage

Roth's spot, a white core visible in the center of the hemorrhage

AGE-RELATED MACULAR DEGENERATION, AMD

Age-related macular degeneration, also known as age-related macular degeneration, due to the aging population, the incidence of AMD has a tendency to increase year by year. Studies have shown that the pathogenesis of AMD is the result of a combination of environmental and clinical factors. Environmental risk factors include age, smoking history, cardiovascular disease history, oxidative stress, and hyperlipidemia.

Clinically, AMD is generally divided into dry and wet types. The former is more common, and about 90% of AMD is dry, while the latter is extremely harmful to visual function, and dry AMD can sometimes transform into wet AMD. The pathogenesis is not completely clear, currently it is believed that AMD is a kind of age-related degeneration of choriocapillary layer-Bruch membrane-RPE-outer retina, which eventually leads to the imbalance of growth factors in the local microenvironment of RPE and Bruch membrane, thus forming Choroidal neovascularization (CNV), which makes the lesion progress and worsen.

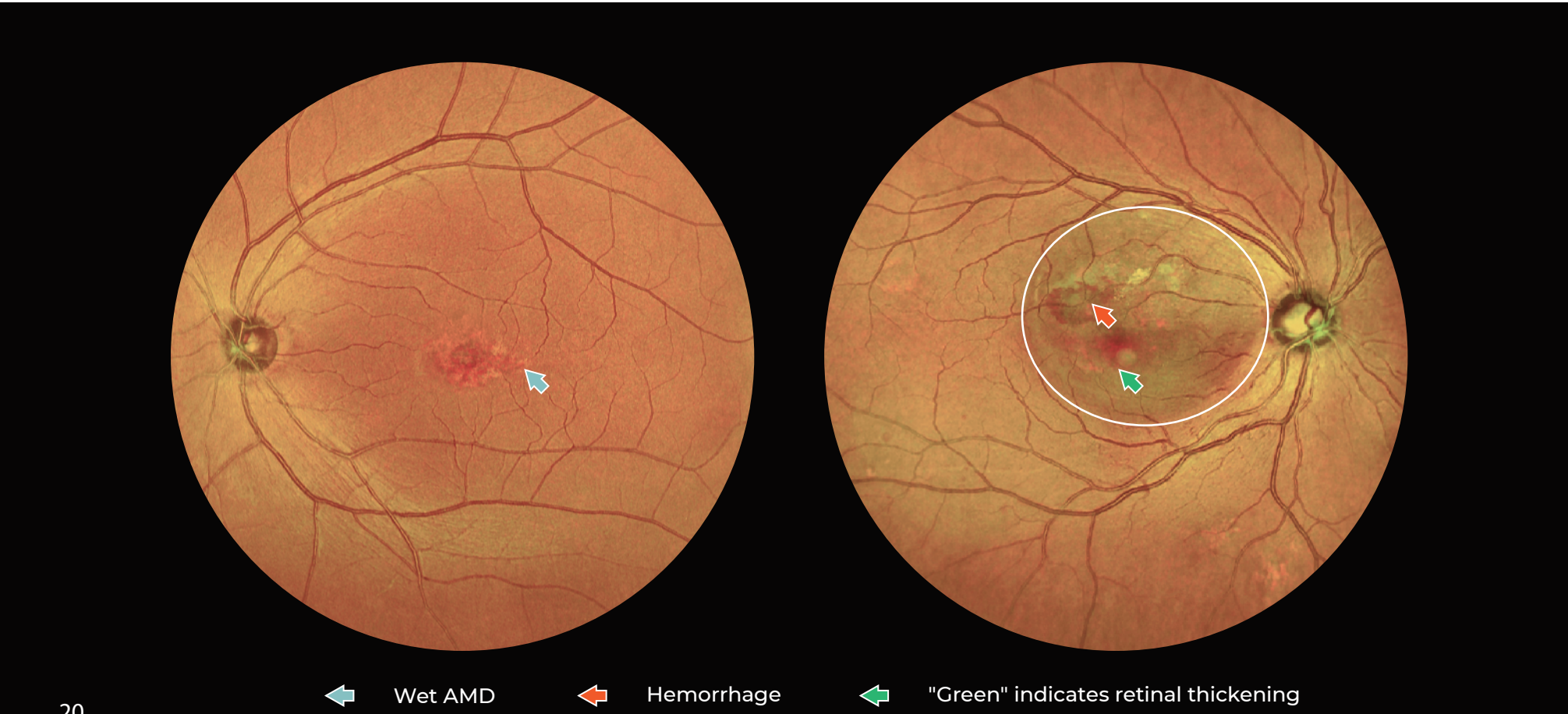

WET AMD

COLOR:

Lnhomogeneous reflection at the central fovea indicates irregular changes in the RPE layer, and the yellow-green surrounding area indicates retinal thickening;

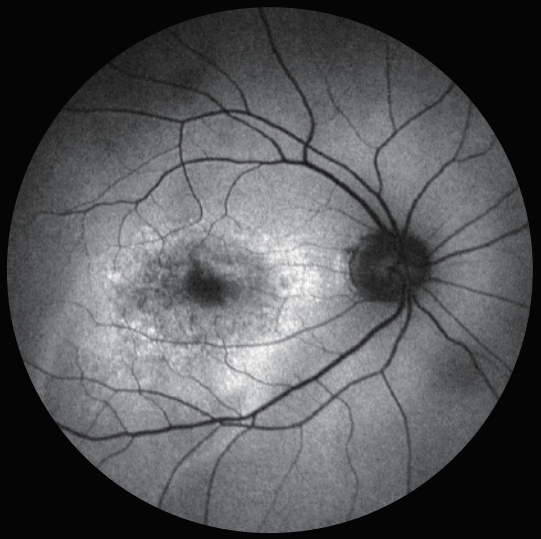

FFA:

Local hyperfluorescence in the macular area, with dot-like hypofluorescence in between

Choroidal neovascularization can be seen in the early stage of FFA, and the leakage is enhanced in the late stage. Hyperfluorescence and patchy hypofluorescence can be seen around.

ICGA shows choroidal neovascularization with clear shape and peripheral hypofluorescence

POLYPOIDAL CHOROIDAL VASCULOPATHY, PCV

Polypoidal choroidal vasculopathy (PCV) is clinically characterized by orange-red nodular lesions under the retina and polypoid structures (Polyps) at the end of the abnormal branched vascular network (BVN) of the choroid.

The disease is more common in people of color, and the age of onset ranges from 20 to 90 years old, with an average age of onset greater than 50 years old. Asian races are more common in males and one eye, while European and American races are more common in women and both eyes. A small number of patients have no obvious symptoms and are found incidentally during examination; most patients present with acute or chronic vision loss, metamorphopsia or black shadows in front of the eyes. Acute vision loss is mostly secondary to spontaneous rupture of Polyps, causing subretinal hemorrhage in the macular area, or even vitreous hemorrhage, resulting in vision loss.

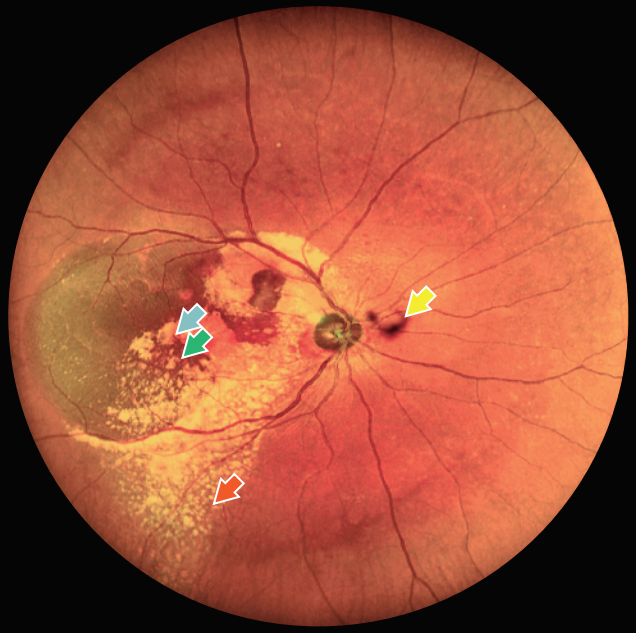

Subretinal hemorrhage

Hemorrhage

Exudate

Weiss ring

Subretinal hemorrhage

Orange-red lesions "Polyp"

Excudate

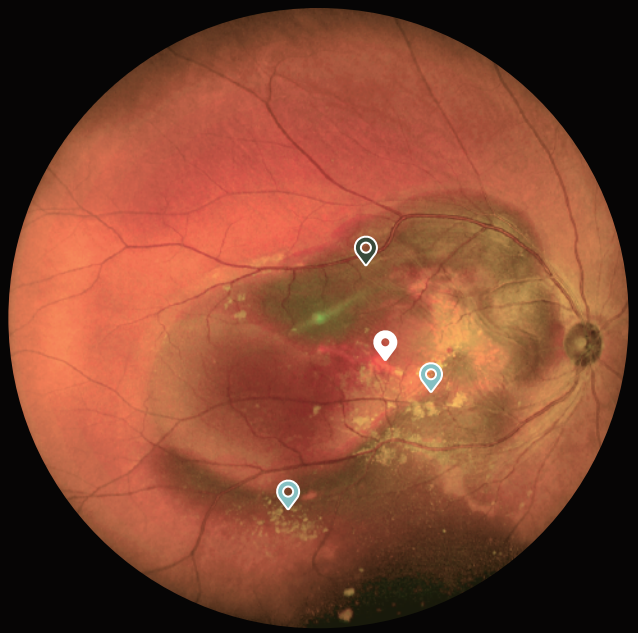

Macular area subretinal hemorrhage, retina and subretinal massivePatchy yellowish-white hard exudation.

Massive subretinal hemorrhage in the macular area, retinal punctate and flaky yellow-white hard exudates, and multiple orange-red lesions above the fovea and on the temporal side.

COLOR:

Orange-red punctate lesions can be seen in the fovea, and patchy RPE irregular change areas can be seen above and below it;

FFA:

Shows multiple hyperfluorescence in the macular area

ICGA:

Shows polypoid structures with hyperfluorescence, and abnormal branched vascular network of the choroid can be seen above, Surrounded by low fluorescence.

COLOR:

Large subretinal hemorrhages can be seen in the macular area, and orange-red lesions can be seen above the fovea;

Late stage FFA:

Macular hemorrhage can be seen covering hypofluorescence, fluorescence leakage above the nose of the macular fovea, and large oval fluorescence accumulation in the macula.

MACULAR HOLE

Macular hole refers to the damage of retinal tissue in the macular area caused by various reasons, and tissue defect occurs from the inner limiting membrane of the retina to the photoreceptor cell layer, forming a hole. According to the cause of the disease, it is divided into secondary and idiopathic macular hole. Secondary macular holes can be caused by eye trauma, macular degeneration, long-term CME, high myopia, etc. Idiopathic macular hole occurs in the elderly with no other predisposing eye diseases and relatively healthy eyes. It is more common in women. The etiology is unclear. It is currently believed that the contraction of the posterior vitreous cortex plays an important role in the tangential pulling force of the macula.

A well-defined hole is visible in the macular area, and the hole is dark red.

Macular hole

MACULAR HOLE - LAMELLAR HOLE

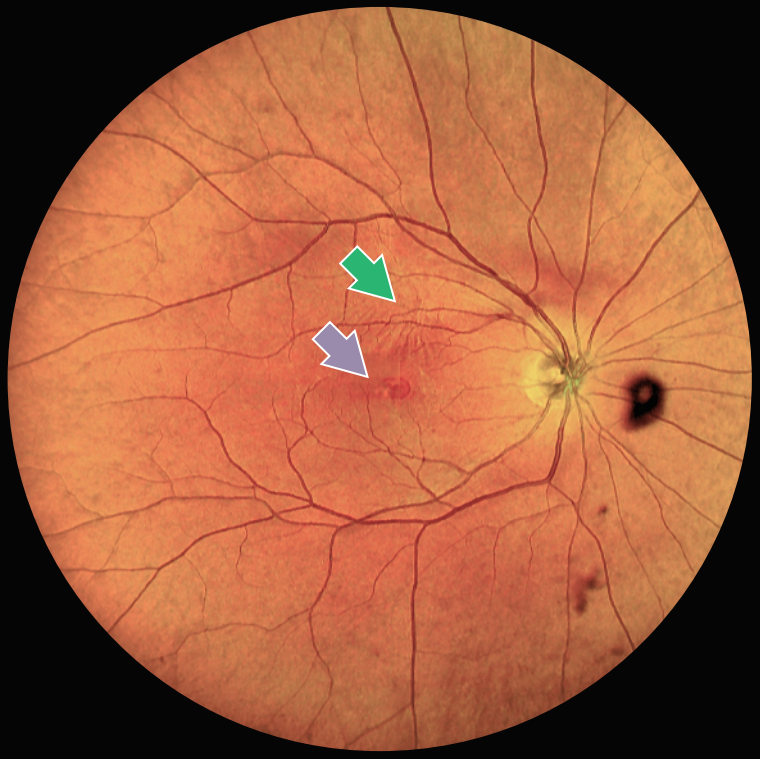

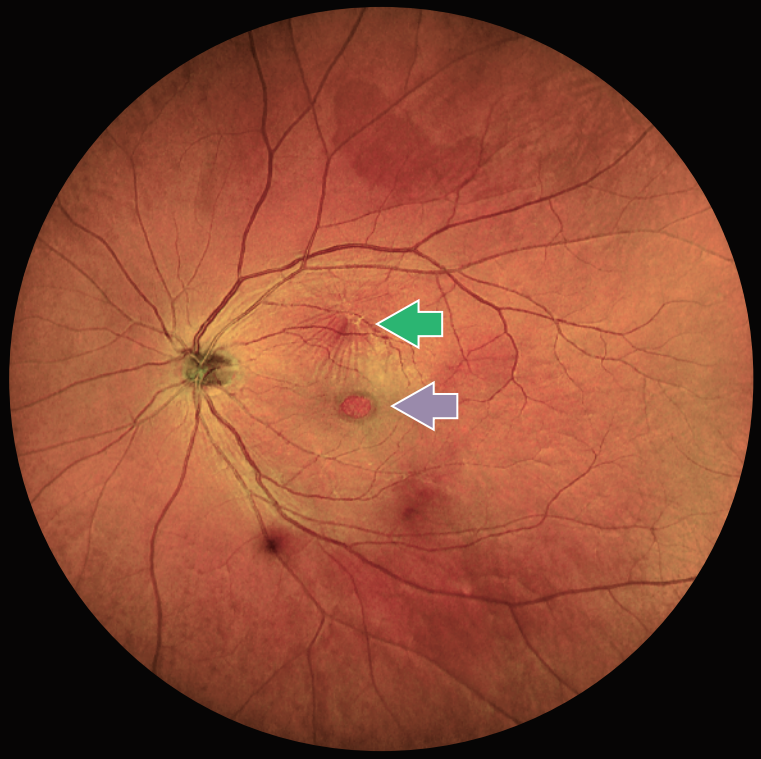

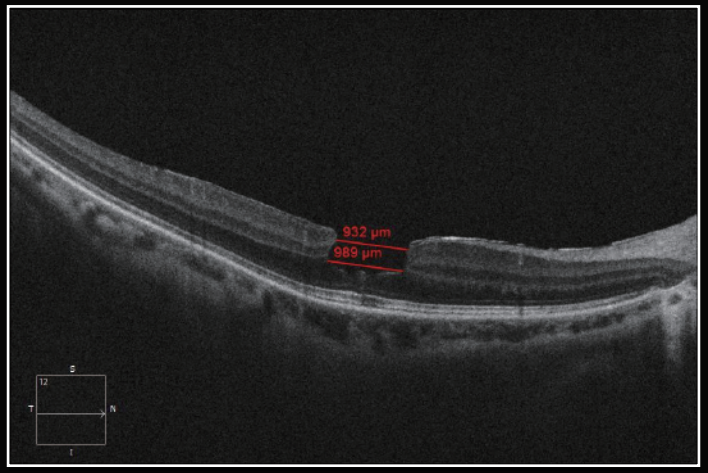

Macular hole

Anterior membrane

MACULAR PRERETINAL MEMBRANE

Macular epiretinal membrane is caused by various reasons by retinal glial cells and RPE cells migrating to the vitreous retinal interface and proliferating to form fibrous membranes. The anterior retinal membrane can occur in any part of the retina. The fibrous membrane occurring in and near the macula is called the macular epiretinal membrane, which is referred to as the anterior macular membrane.

Yellow and white proliferating film can be seen in the macular area, and the proliferating film can be seen pulling the radial texture of the retina.

Anterior membrane

Optical contrast (same eye)

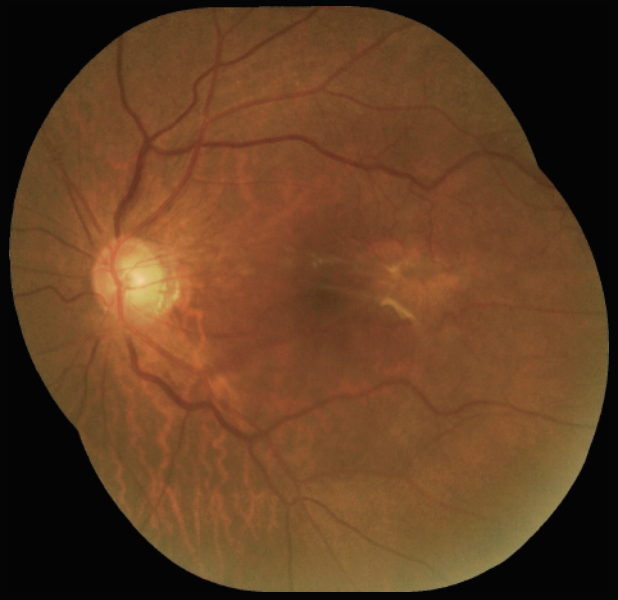

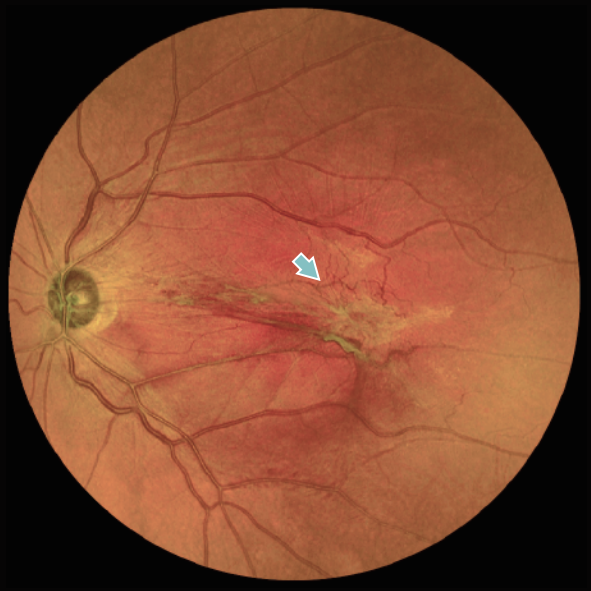

Optical contrast

Anterior membrane

competitors images quality

Apollo fundus images

MORNING GLORY SYNDROME

It's a specific type of optic nerve defect. Its features include optic nerve defects. Characteristic retinal vascular abnormalities. Neurogliosis and transformation, and pigmentary changes around the optic disc. Because fundus shape like a blooming morning glory named. The pathogenesis is unknown, which may be caused by the failure of the uppermost part of the embryo fissure to close, resulting in the backward prolapse of the optic disc and its surrounding area, or the abnormal development of fovea glia of the optic disc. Most are monocular. The most common complication is retinal detachment. Typical retinal detachment occurs around the deeply depressed optic disc and is mostly confined to the posterior pole of the retina.

Fundus examination: the optic disc was large, pink in the periphery, with deep funnel-shaped depression, dense white mass without obvious structure in the center, such as stamen, obscurating the running form of deep blood vessels. There are typically grey-gray or gray-black protrusion rings around the optic disc, accompanied by sporadic pigmentation, or choroidal atrophy of the retina. There are 20 to 30 blood vessels radially distributed at the edge of the optic disc.

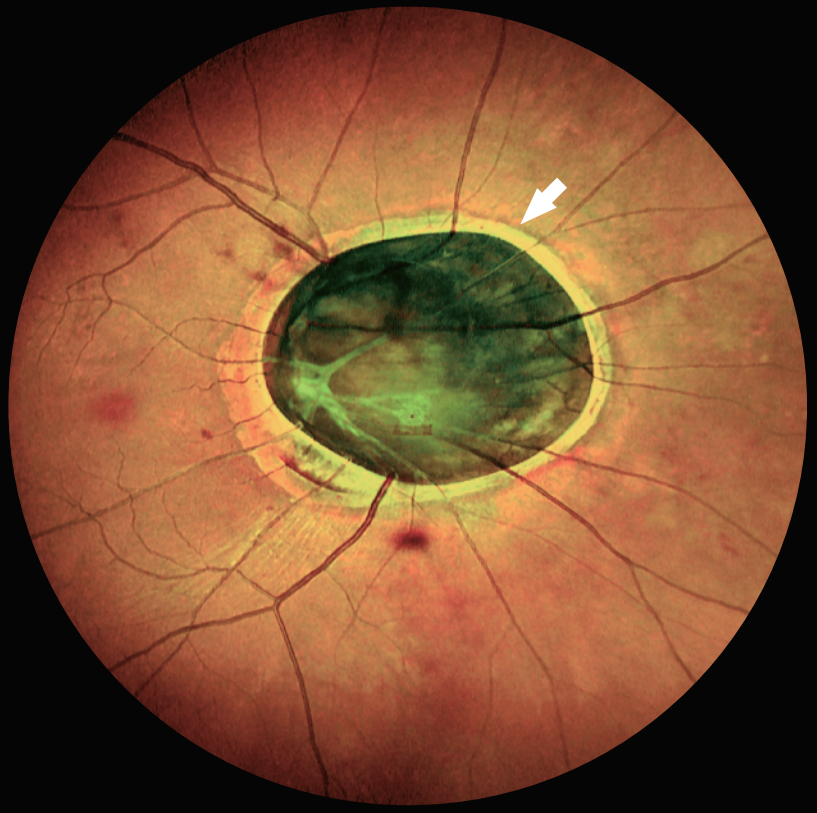

Key points of diagnosis:

1: Poor eyesight. Strabismus. nystagmus

2: fundus characteristic morning glory pattern change

3: fundus angiography assisted diagnosis

4: Characteristic changes of B ultrasound and orbital CT

⬅ Deeply infundibular

OPTIC DISC DRUSEN

The presence of a hyaline substance in the optic disc is often binocular, the cause of which is unclear; it may be due to congenital developmental abnormalities and is usually familial. Because the druse is often buried deep in the optic disc, it's also known as a buried optic disc druse.Fundus observation:

Yellow and white nodular prominences can be seen on the superficial optic disc, mostly in the shape of mulberries. The edge of the optic disc is not clear, but it can also fuse into a large irregular mass, protruding into the vitreous body. The drusen of the buried optic disc are found to be slightly enlarged, uplifted up to 1/2 to 3D, and the boundary is unclear with irregular undulations.

Retinal blood vessels curve and crawl on the optic disc, giving the appearance of pseudo-optic disc edema. Retinal blood vessels are normal, though sometimes slightly elevated on the surface of the drusen, or obscured, or undulating. Retinal veins may be congested, retinal bleeding can be seen near the optic disc, occasionally exudative spots, and even neovascularization. Anterior ischemic optic neuropathy is a common complication with age.

Highlighted bumps after fusion

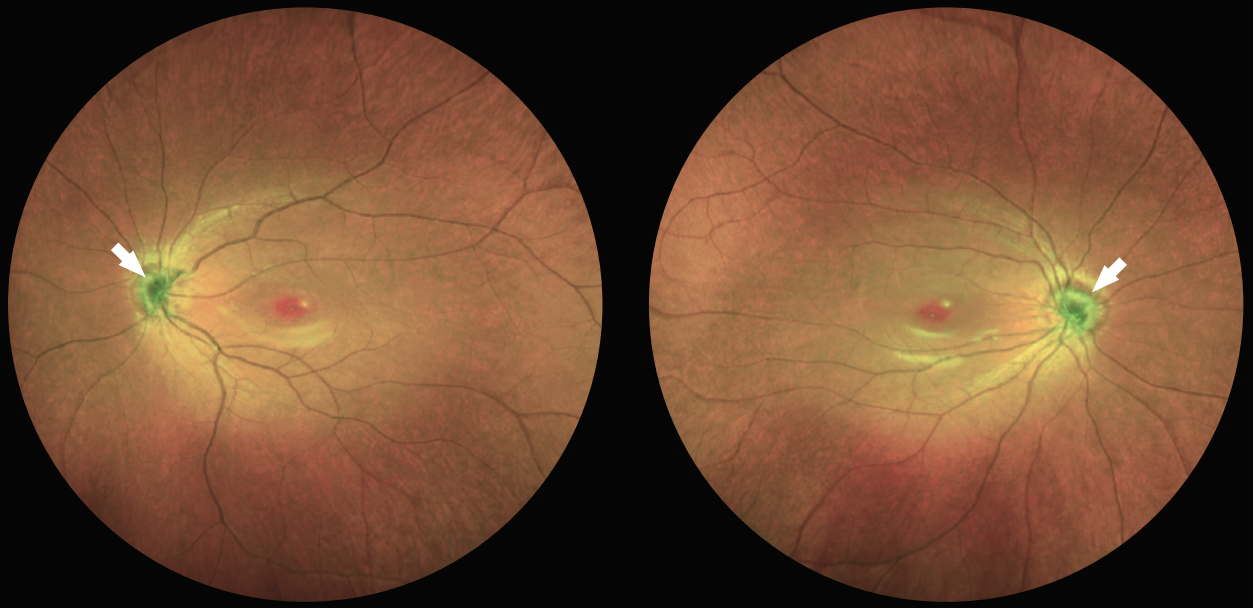

CONGENITAL PRE-OPTIC DISC VASCULAR LOOP

This condition, also known as preretinal vascular loop or intravitreal vascular loop, involves the presence of vascular loops branching from retinal vessels, not linked to embryonic vasculature. It is speculated that irregular vascular buds form in the vitreous artery during embryonic months 4 to 7. As the surrounding tissue shrinks during development, the vascular loop persists.

During fundus examination, two types of loops can be distinguished, arterial and venous. To differentiate between them, fluorescein fundus angiography is necessary. One end of these vascular loops originates at the primary branch of the central retinal artery on the surface of the optic disc, while the other end may connect to another branch on the optic disc's surface or at its edge. In some cases, it may even penetrate the inner surface of the optic disc. The size and shape of these loops can vary, appearing as long, twisted single loops or multiple intertwined loops that may protrude into the vitreous humor.

While loops of veins are relatively rare, they can be found on or near the surface of the optic disc, often accompanied by pulsatile veins. This condition is associated with the potential complication of anterior ischemic optic neuropathy, especially as patients age.

FFA:

No leakage

Vascular loop

Clinical manifestations:

Often asymptomatic, difficult to detect, mostly monocular

RETINAL MYELINATED NERVE FIBERS

Optic nerve myelin fibers grow from the center to the periphery, and the optic nerve myelin reaches and terminates at the rear end of the optic disc cribriform plate at birth. Normally, the optic nerve is surrounded by myelinated fibers from the lateral geniculate body to the scleral cribriform plate. Fundus examination after birth does not reveal myelinated nerve fibers. If there is abnormal development, within one month or a few months after birth, the myelin sheath will continue to grow, surpassing the level of the cribriform plate, reaching the retina and even the farther fundus, forming white turbid myelinated fibers..

Most of them are monocular, mostly distributed on the upper and lower edges of the optic disc, and stretch along the direction of nerve fiber walking. Occasionally, isolated pinnae leukoplakia are located near the upper and lower retinal vascular arches away from the optic disc..

The yellow-white myelinated nerve fibers are distributed around the optic papilla, the myopic papilla is dense, and the periphery is sparse and feathery.

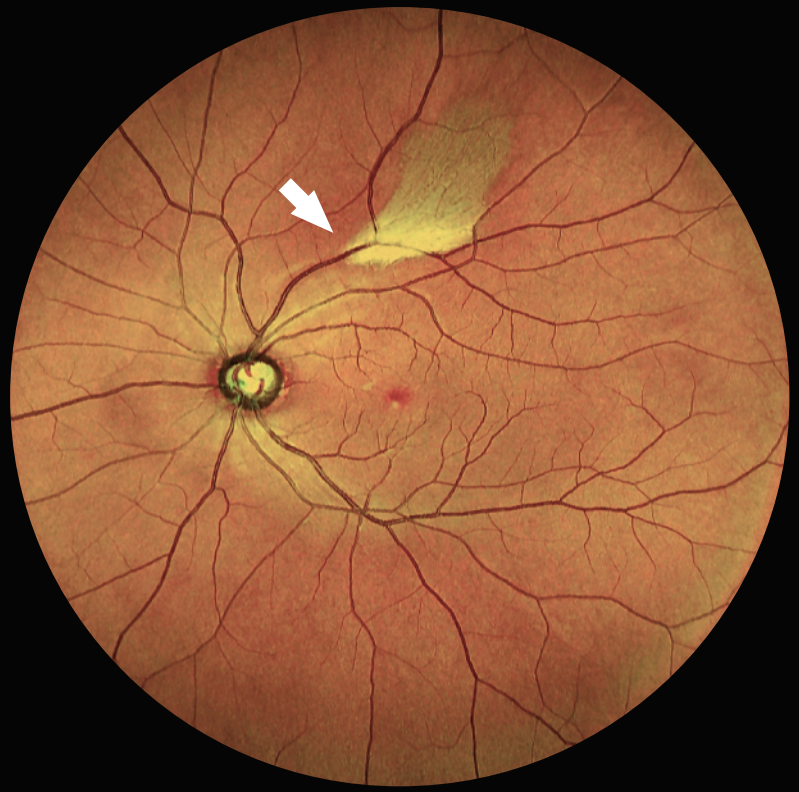

Myelinated nerve fibers

CONGENITAL CHOROIDAL DEFECT

Choroidal defect is a relatively common congenital fundus tissue defect, which is actually a defect of choroid and retinal pigment epithelium. Most of the choroidal defects are binocular, and occasionally monocular. Patients have poor vision, often with nystagmus and strabismus. Its clinical manifestations are both typical and atypical.

Typical choroidal defect

Mostly in both eyes, the defect is often located in the embryonic fissure below the optic disc, and can also be found in other parts of the fundus. Due to the lack of choroid and retinal pigment epithelium in the defect area, gray-white sclera can be seen through the thin retinal neuroepithelium. The extent and shape of the defect area vary greatly. The small ones can be 1~2PD, and the big ones exceed one quadrant. The shape is usually an upright obtuse triangle, shield shape, or ellipse. The top of a large defect may include the entire optic disc or invade a portion of its underside. The peripheral edge of the defect area, in the extreme peripheral part of the fundus, is generally not found by direct ophthalmoscopy. Only by binocular indirect ophthalmoscopy and scleral compression inspection can the arc-shaped boundary be seen. Residual choroidal large blood vessels can sometimes be seen in the defect area, and retinal blood vessels can also be seen on the surface of the defect area, with normal course and interrupted or surrounded by the edge of the defect.

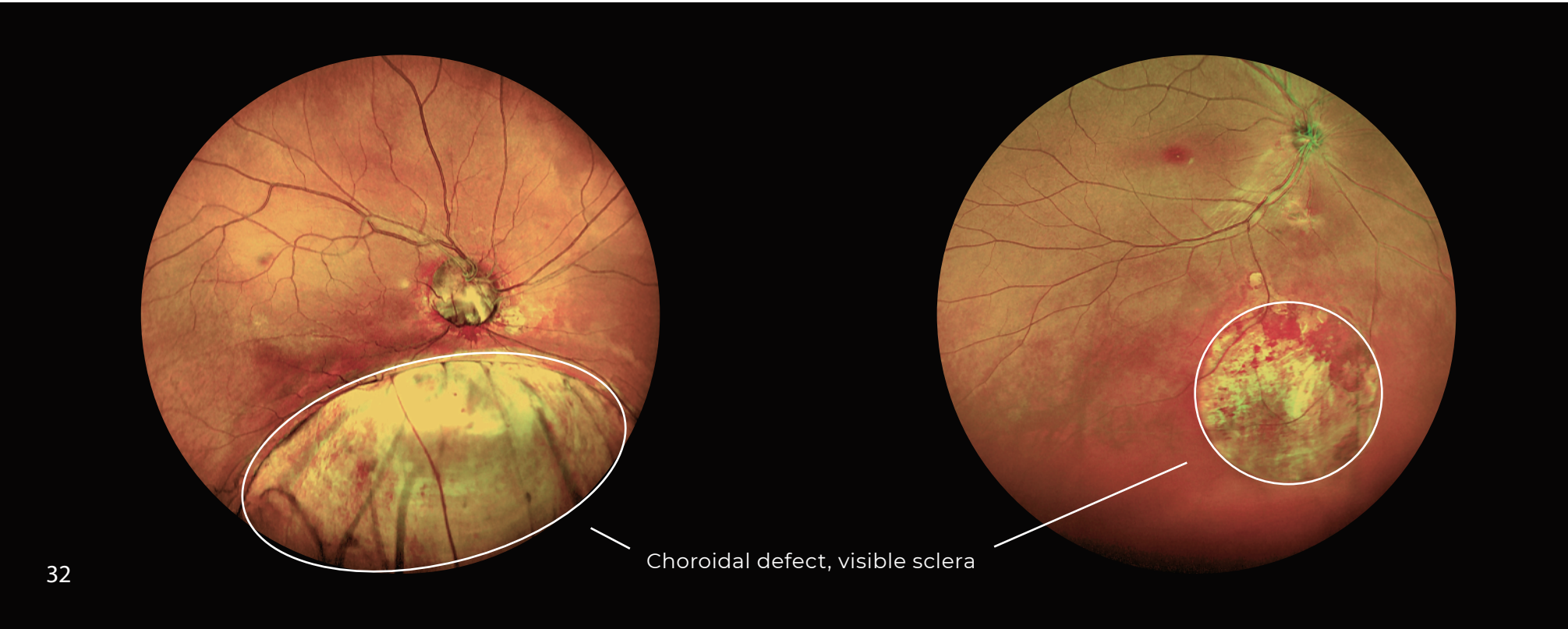

SuZhou MicroClear Medical Instruments Ltd

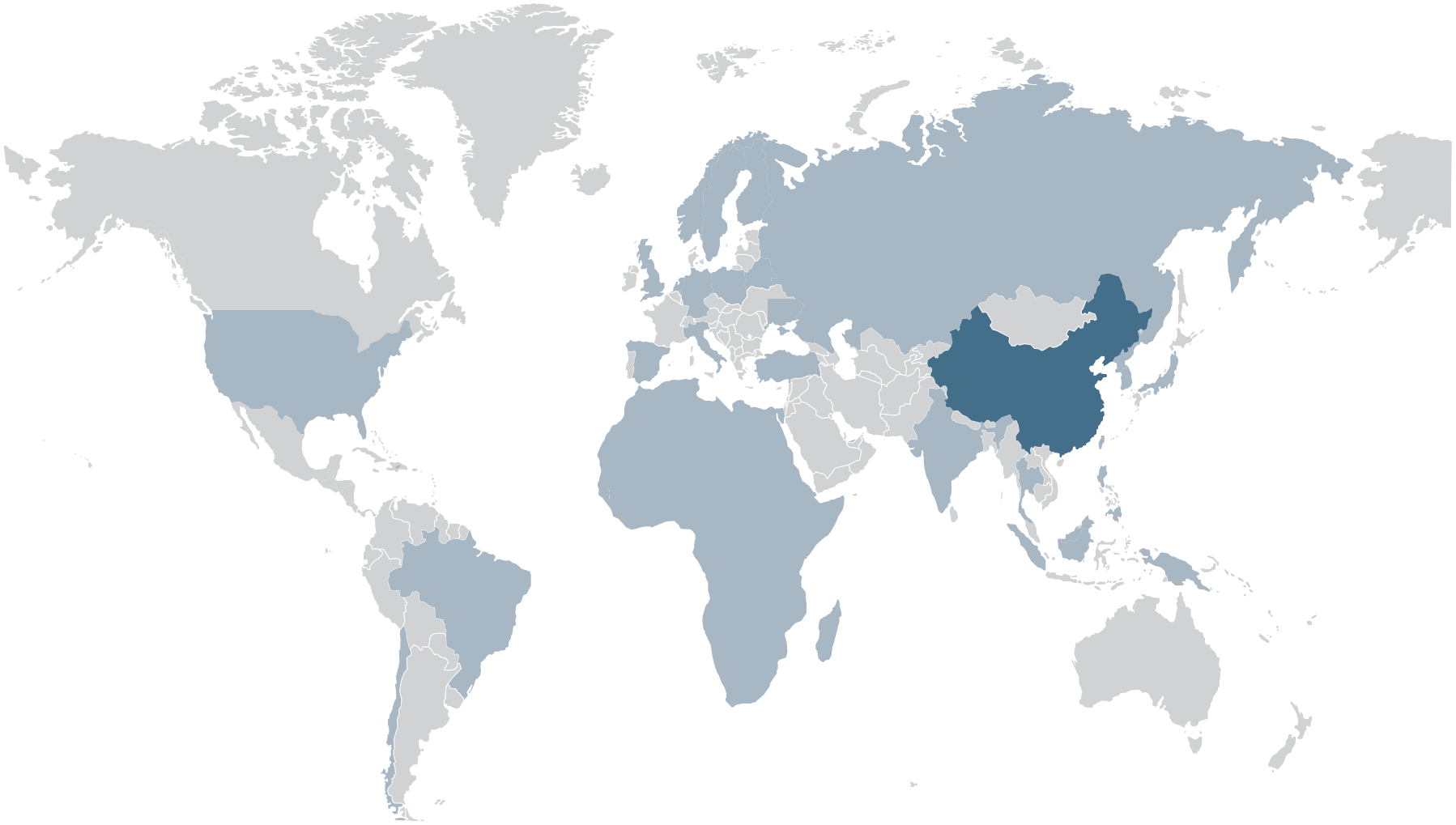

400-900-1708

marketing@microcleartech.com

www.microcleartech.net

Floor 17, Building G2, Artificial Intelligence Industrial Park,
No. 88 Jinjihu Avenue, Suzhou Industrial Park, Suzhou City,
Jiangsu Province, China.