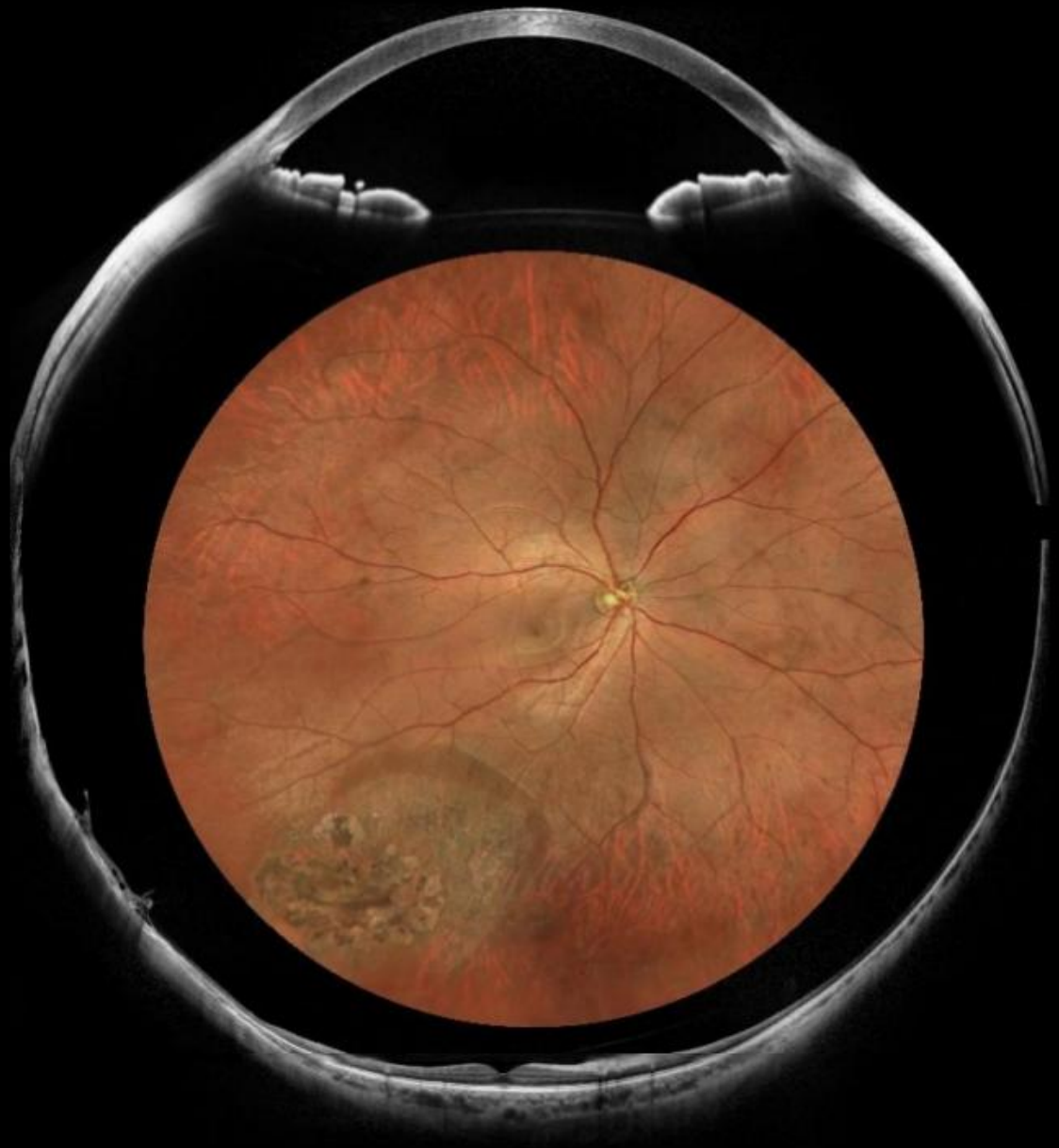

MICRO CLEAR SKY

SKY

Whole-eye Imaging Platform

Clinical Atlas

Cataract

Case1:Cataract &Post-cataract

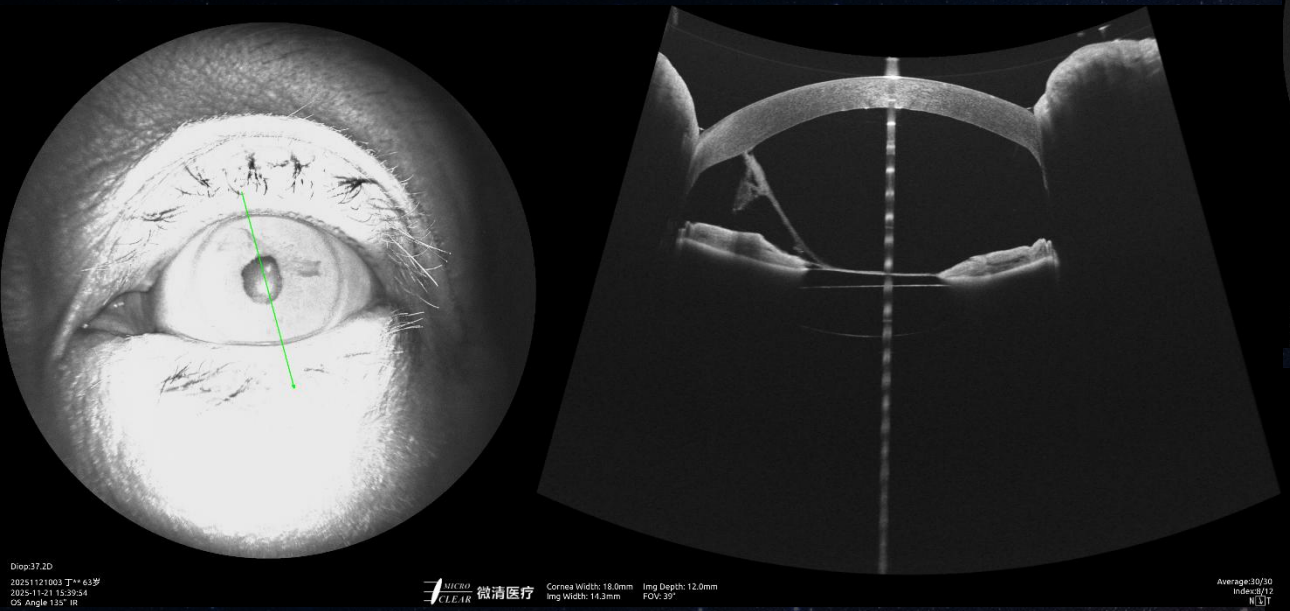

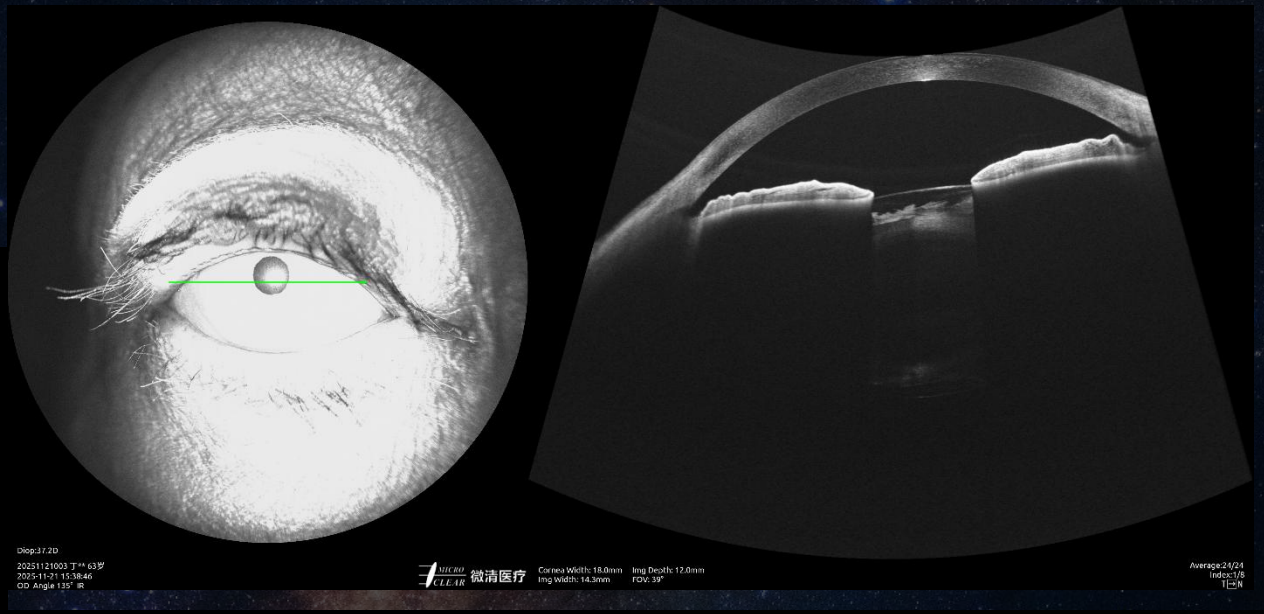

OD Cataract; OS Post-cataract surgery

Both anterior and posterior segments for cataract patients

Fundus macula remains observable even after adjusting laser power

Evaluate pre-operative and post-operative visual acuity improvement

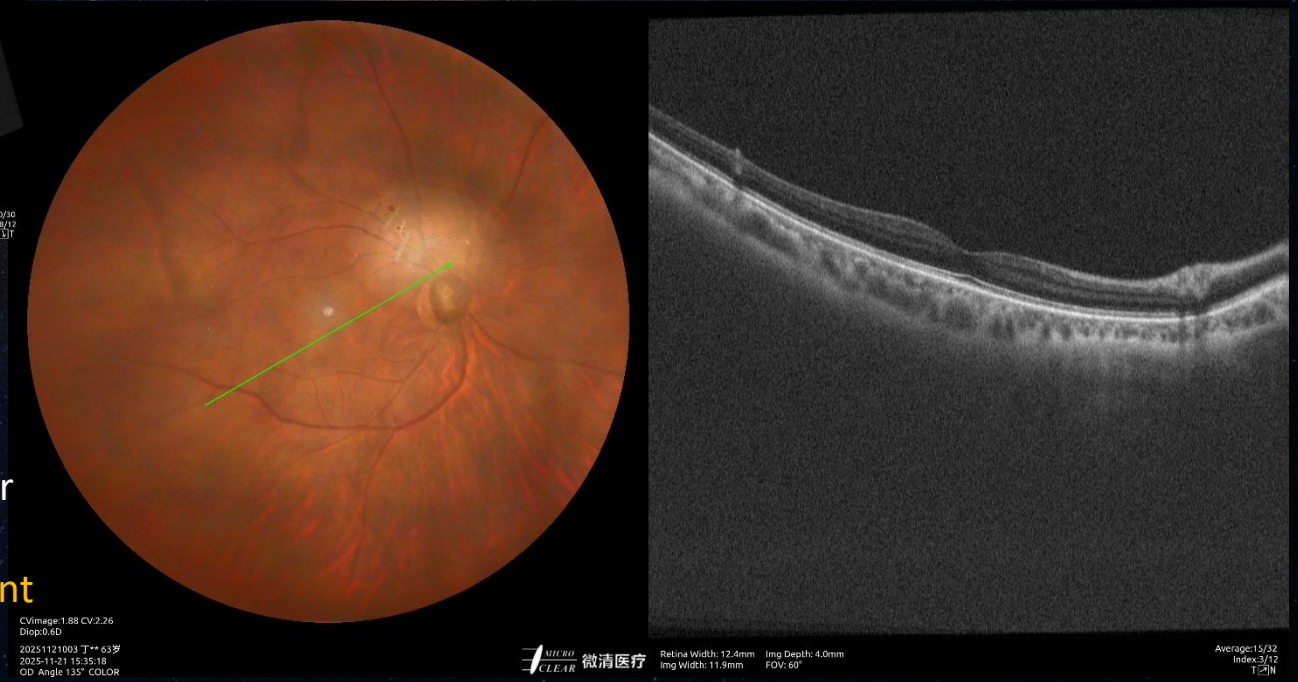

Perfect synergy planar sync tomography meets ultra-wide imaging.

MICRO CLEAR SKY

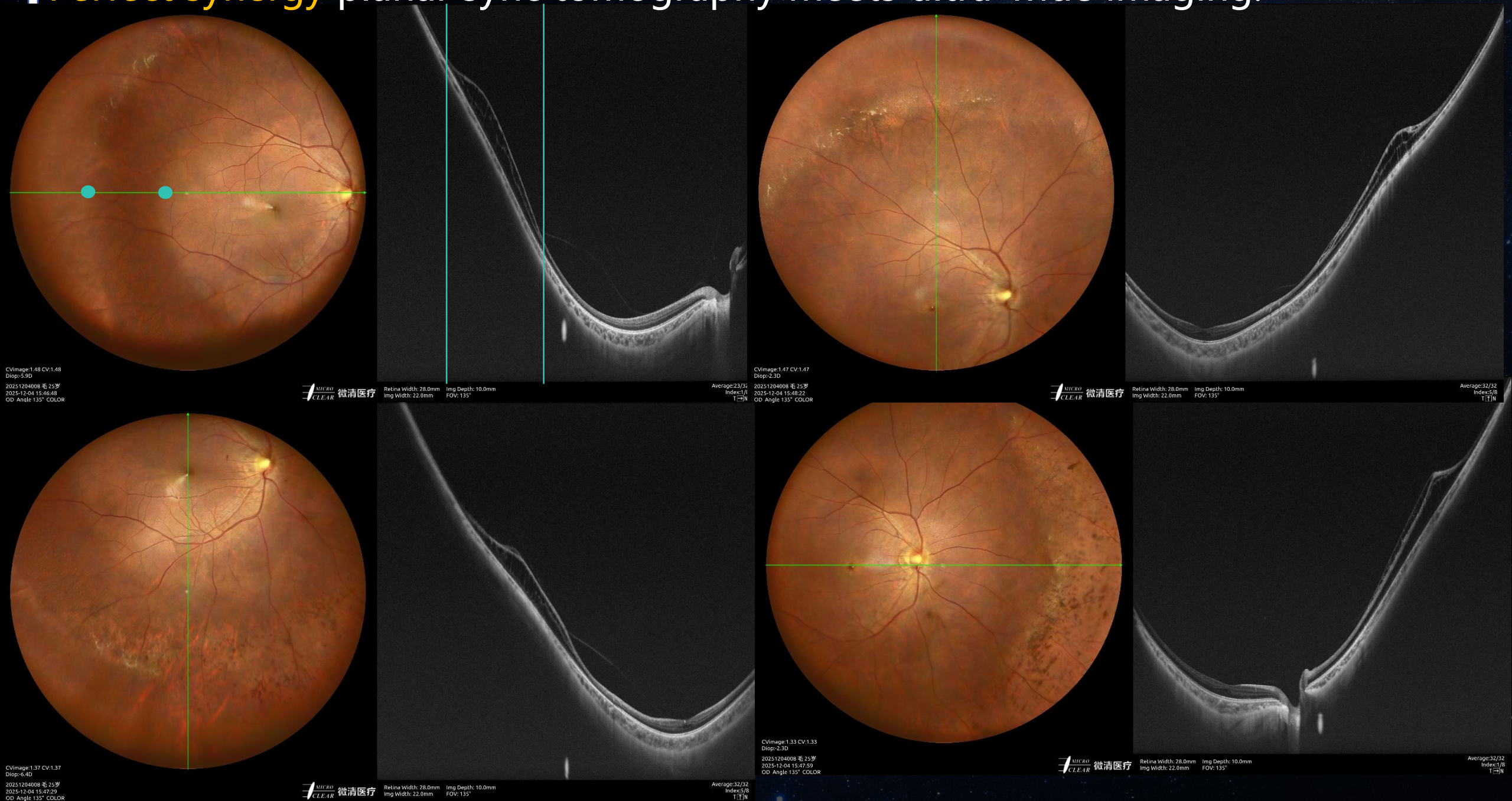

Ends the era of 'suspicious' findings — Any-position OCT delivers certainty.

From the retinal tissue level, it clarifies the severity and type of degeneration, guiding the laser treatment.



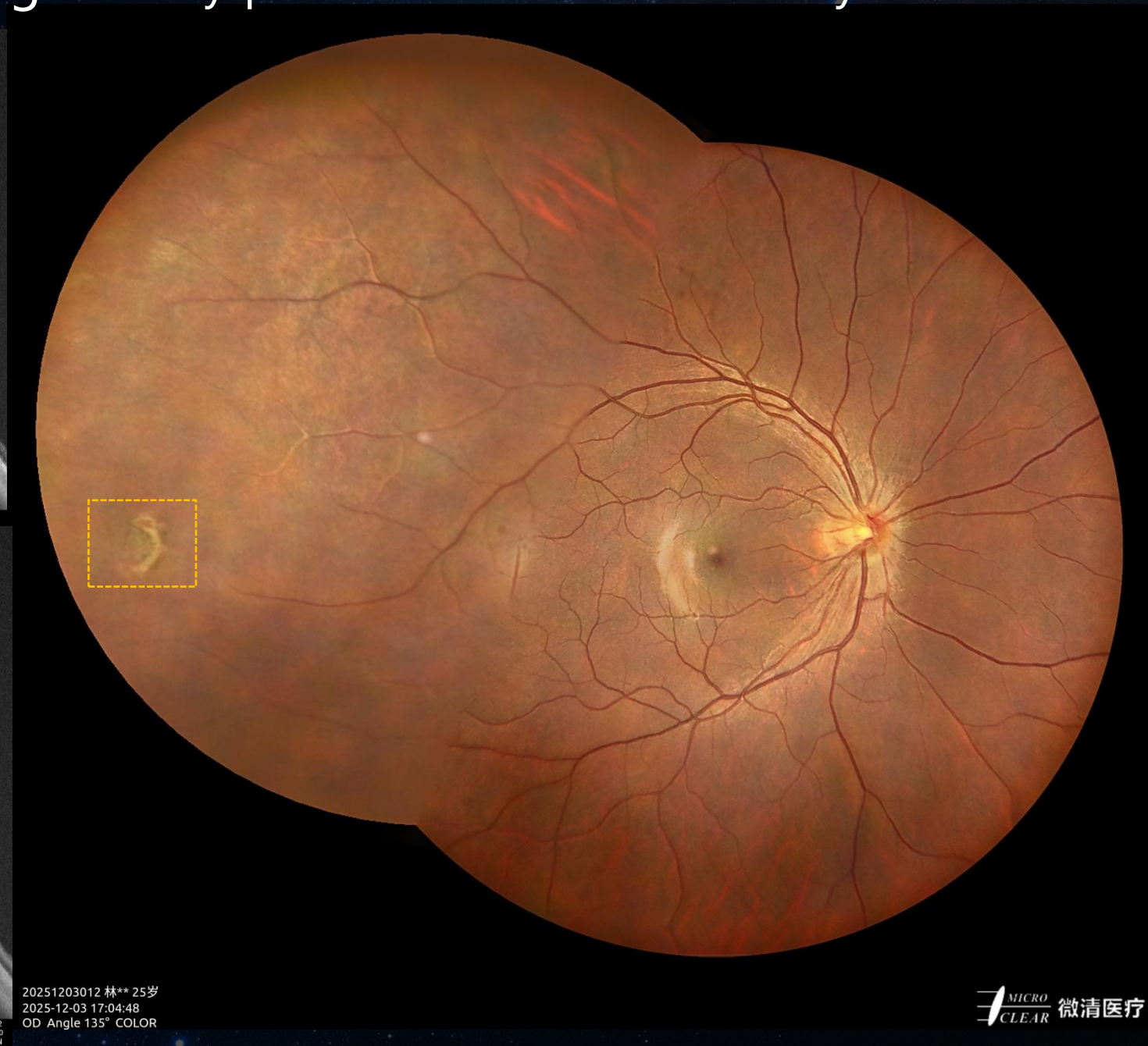

Clear tissue-level visualization yields powerful evidence that empowers clinical decision-making and therapy.

Delineating the extent of degeneration and retinoschisis, thereby guiding the treatment area for laser treatment.



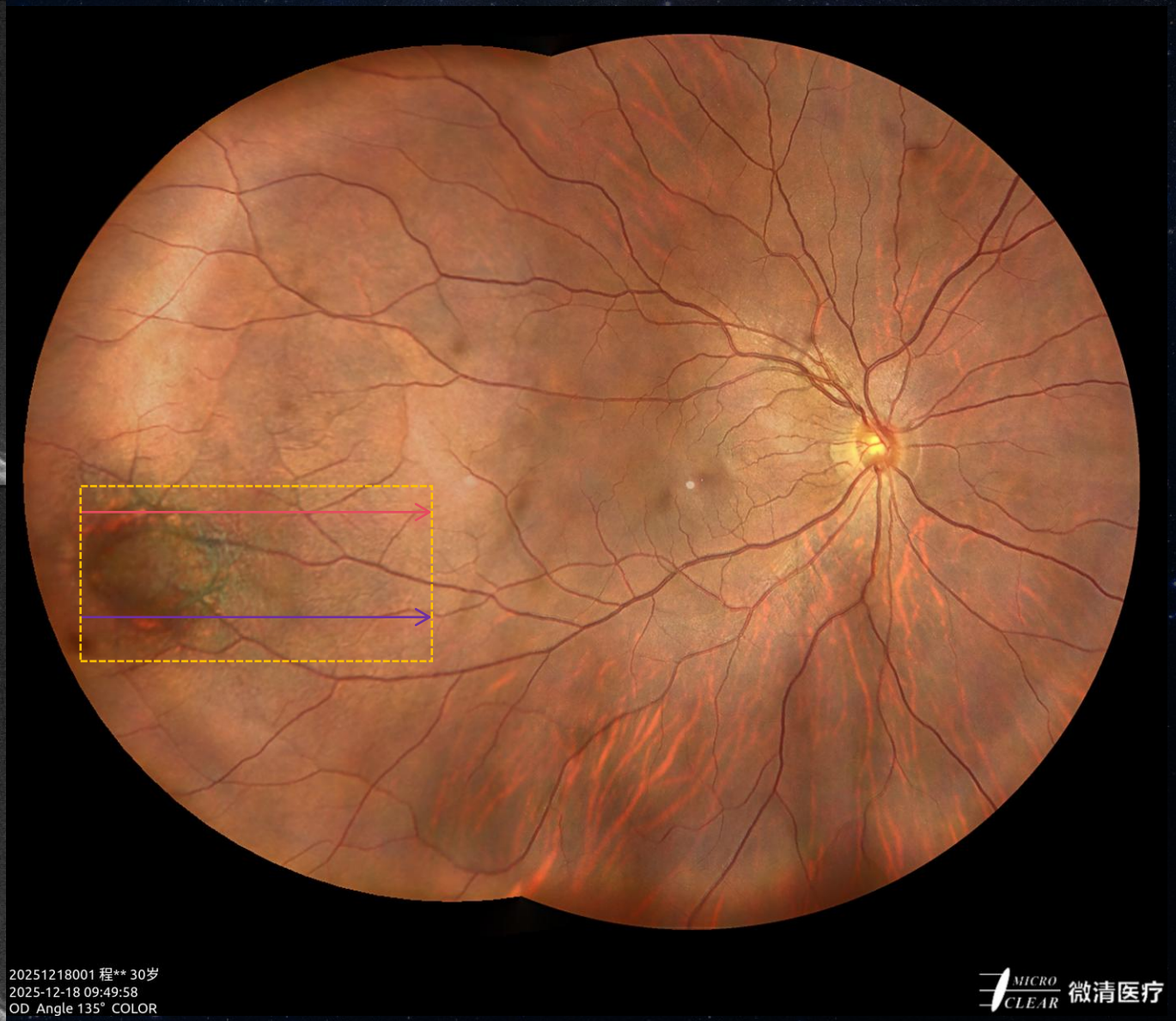

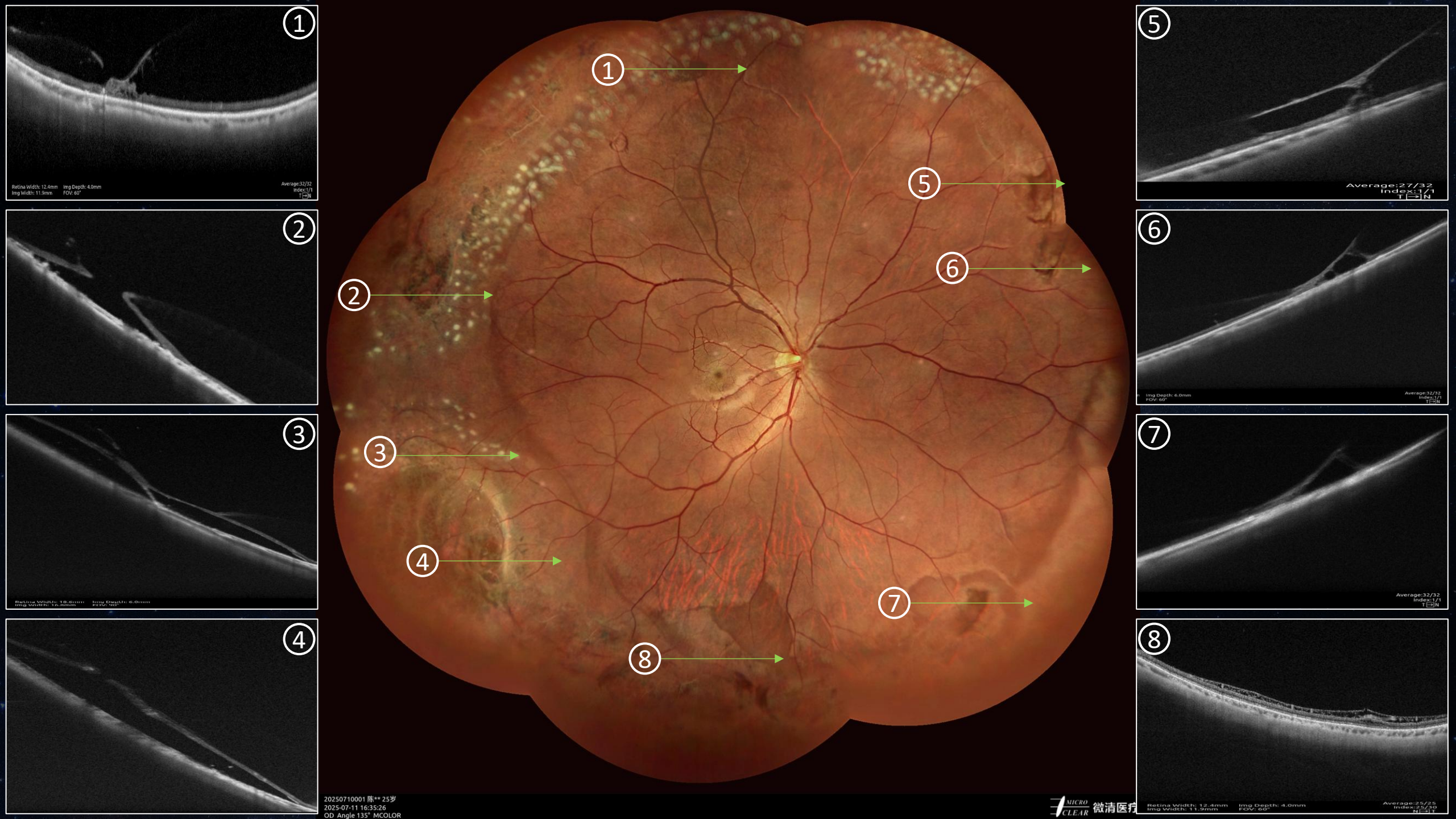
1
2
3
4
5
6
7
8
Retina Width: 12.4mm
Img Width: 11.9mm
Img Depth: 4.0mm
FOV: 60°
Average:32/32
Index:1/1
Average:27/32
Index:1/1
Img Depth: 6.0mm
FOV: 60°
Average:32/32
Index:1/1
Average:32/32
Index:1/1
Retina Width: 12.4mm
Img Width: 11.9mm
Img Depth: 4.0mm
FOV: 60°
Average:25/25
Index:25/30
20250710001 陈** 25岁
2025-07-11 16:35:26
OD Angle 135° MCOLOR
MICRO CLEAR 微清医疗

Retinal Tears post-laser

Hypertensive Retinopathy and Vitreous Traction

崔学森

Hypertensive Retinopathy and Vitreous Traction

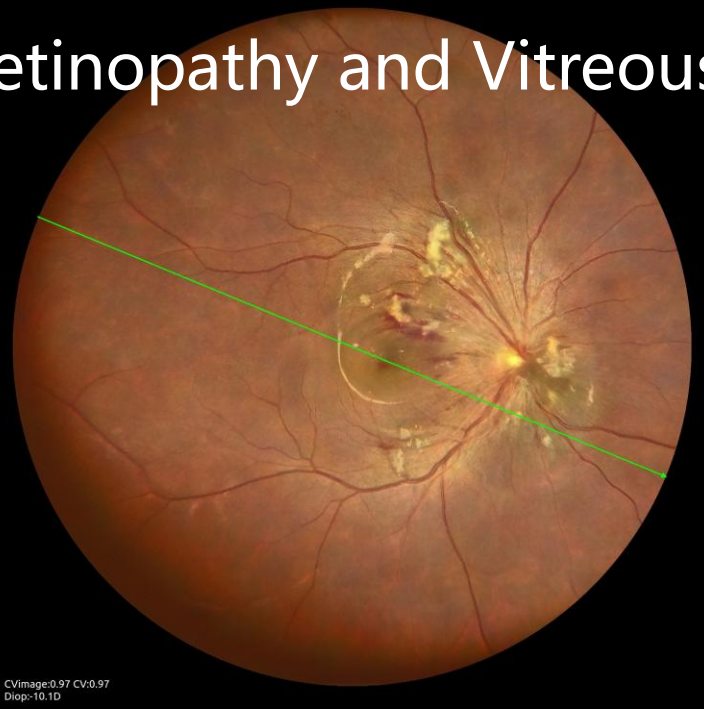

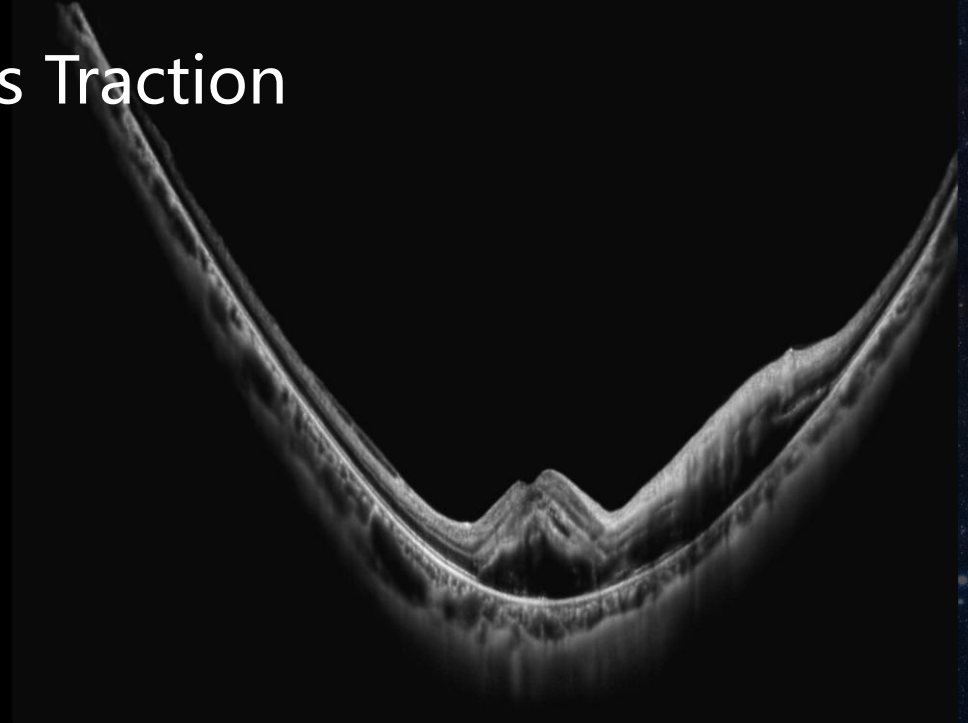

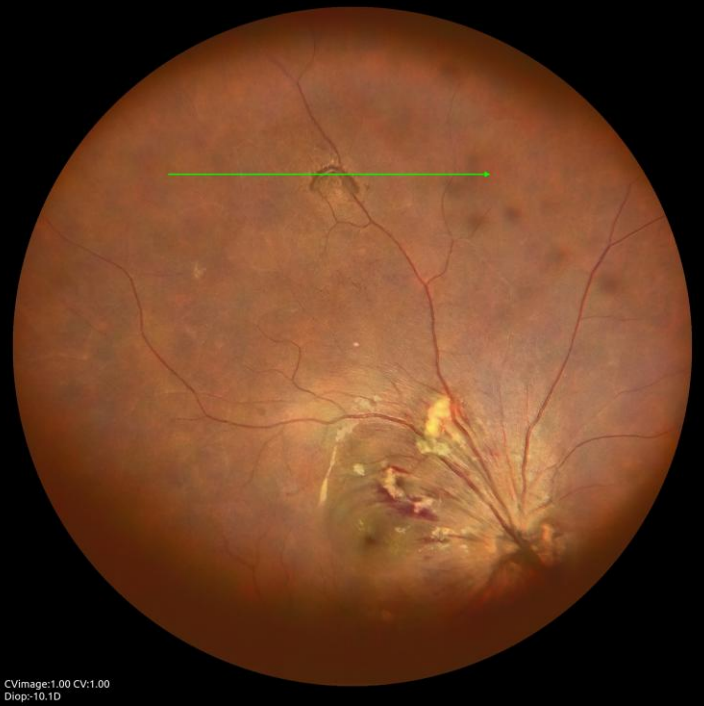

Vitreous Traction

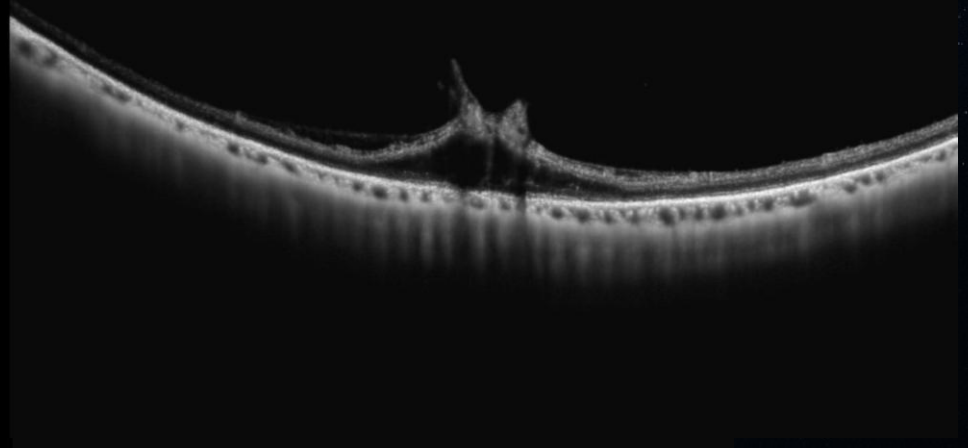

DR and Retinal Tear

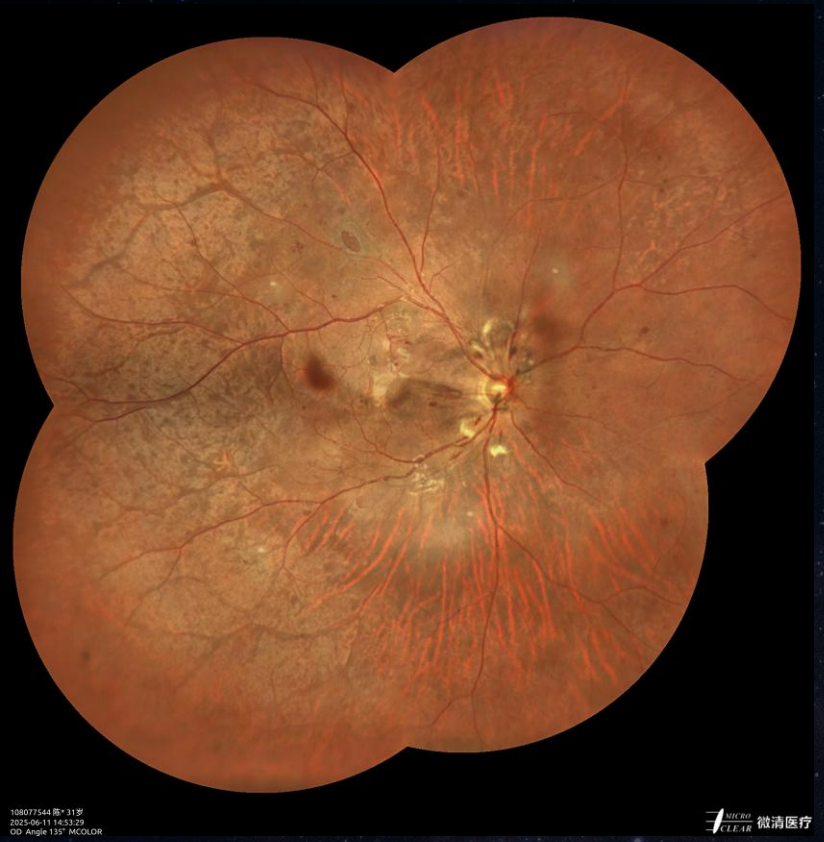

preoperative

3-week
follow-up

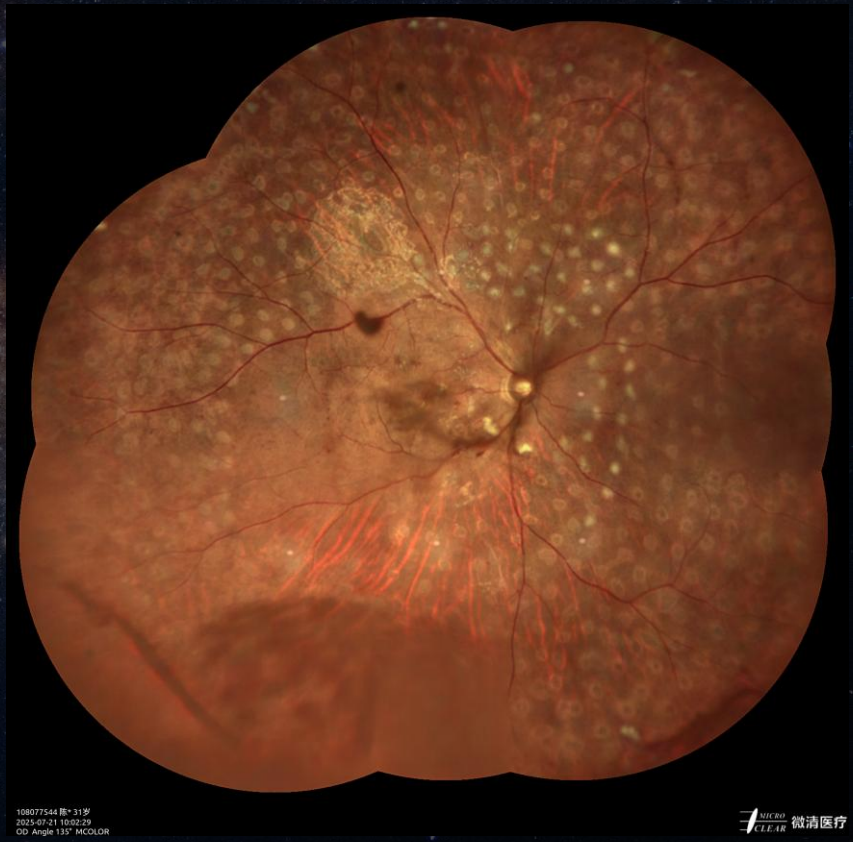

5-week
follow-up

DR and Retinal Tear

PDR & Retinal Detachment



PDR

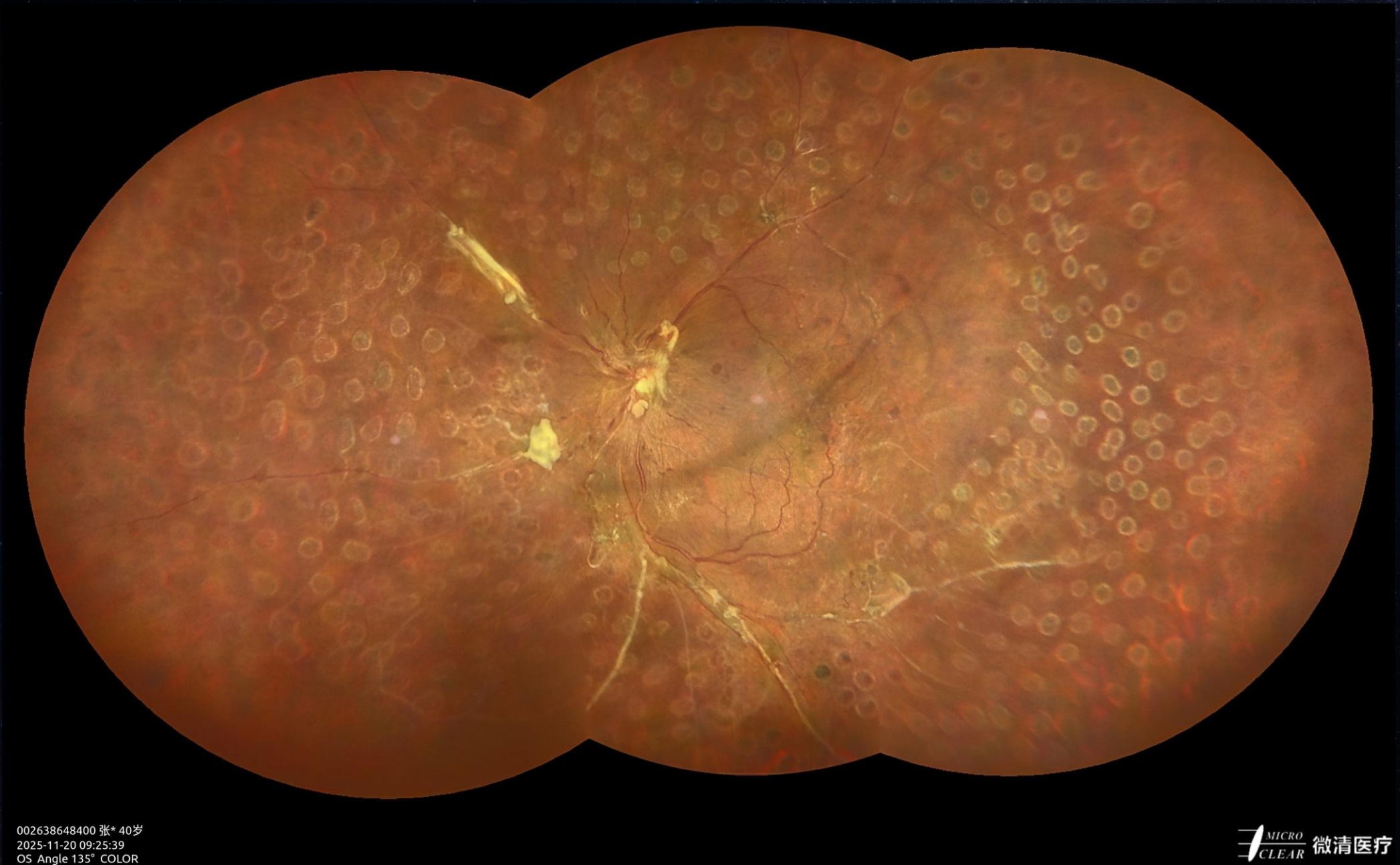

PDR

张明

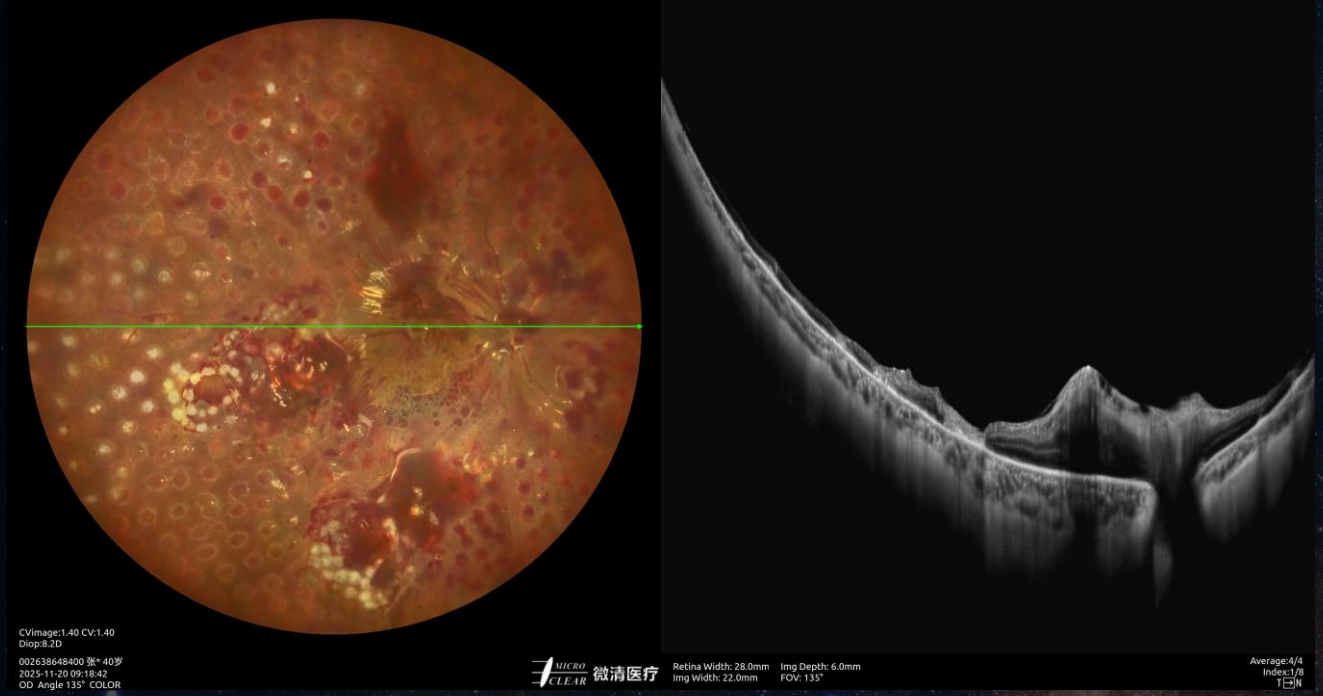
CVimage:1.40 CV:1.40
Diop:8.2D
002638648400 张* 40岁
2025-11-20 09:18:42
OD Angle 135° COLOR
微清医疗
Retina Width: 28.0mm
Img Width: 22.0mm
Img Depth: 6.0mm
FOV: 135°
Average:4/4
Index:1/8

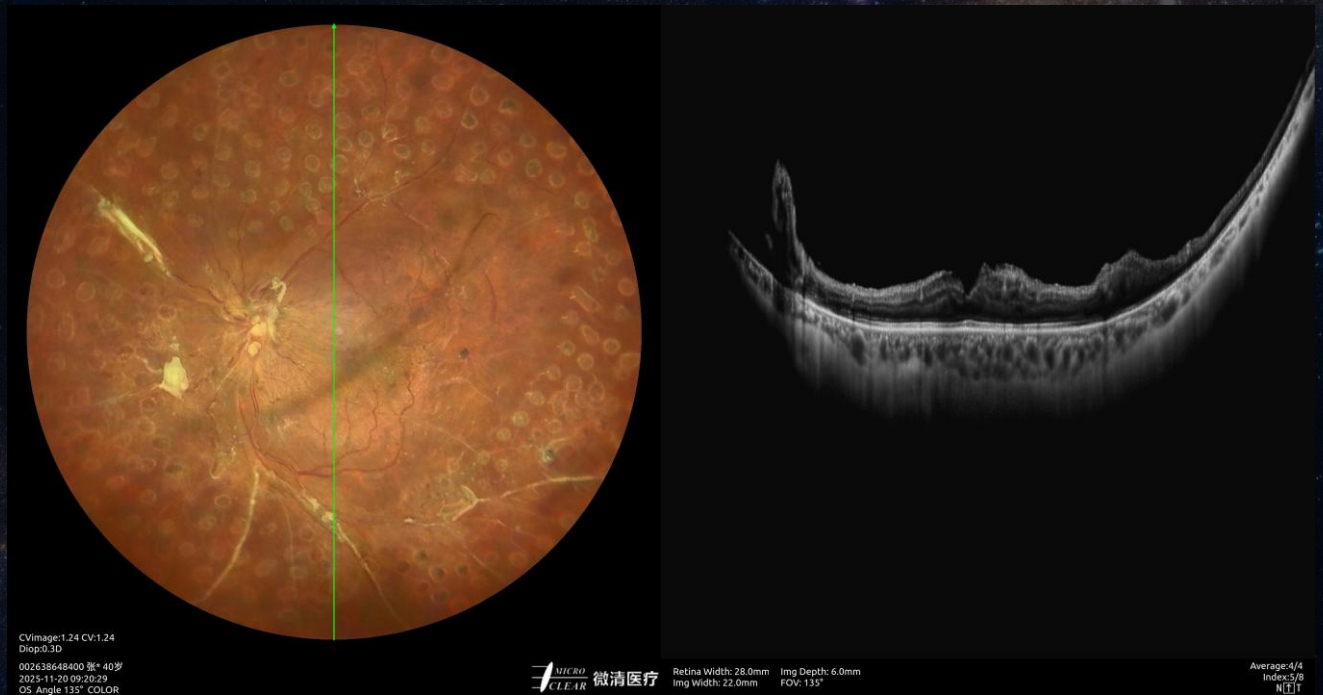
CVimage:1.24 CV:1.24
Diop:0.3D
002638648400 张* 40岁
2025-11-20 09:20:29
OS Angle 135° COLOR
微清医疗
Retina Width: 28.0mm
Img Width: 22.0mm
Img Depth: 6.0mm
FOV: 135°
Average:4/4
Index:5/8

Diabetic Retinopathy

ZXYCJ205

DME

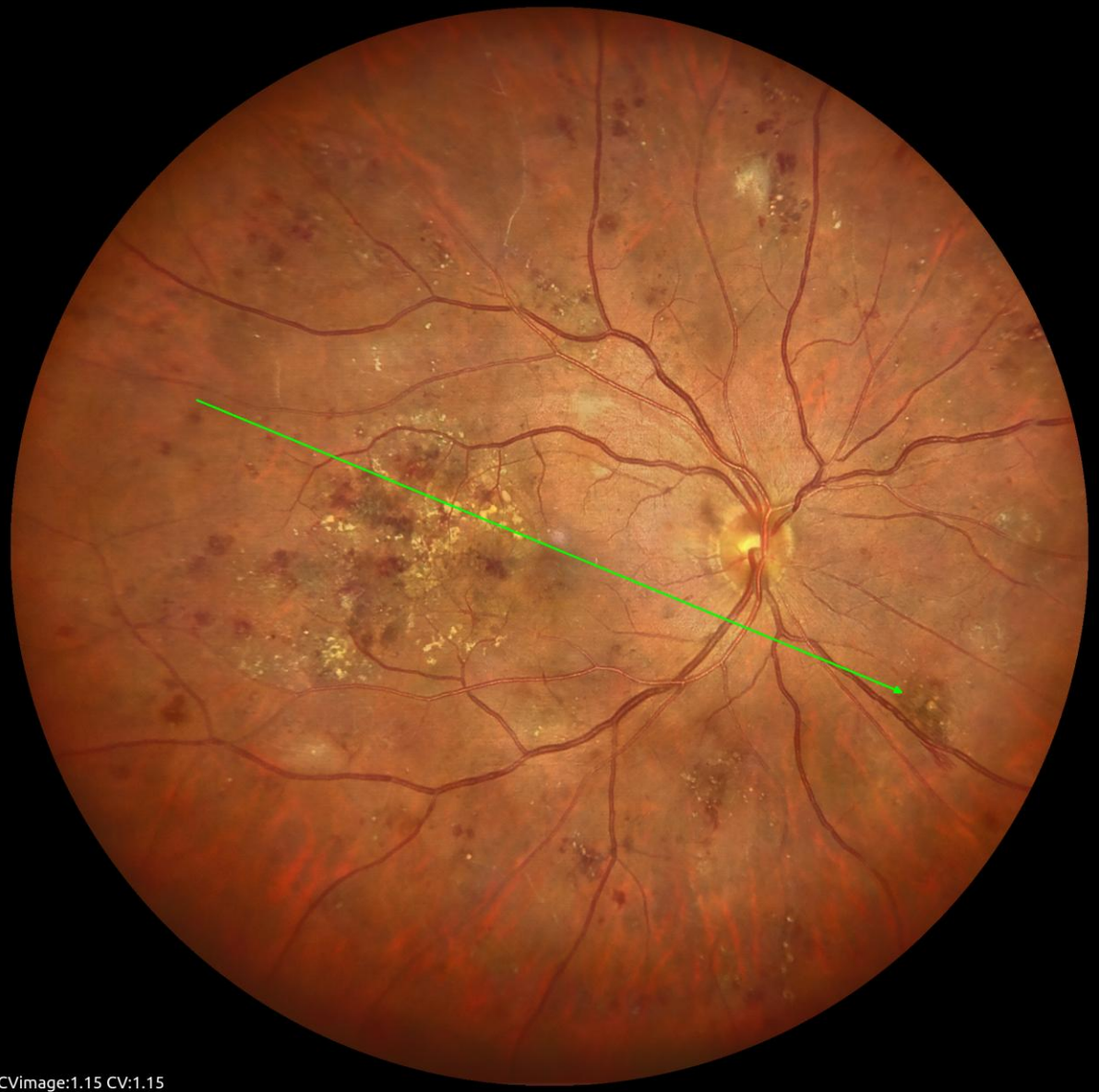
CVimage:1.15 CV:1.15
Diop:0.0D
2025-11-12 11:15:14
OD Angle 135° COLOR

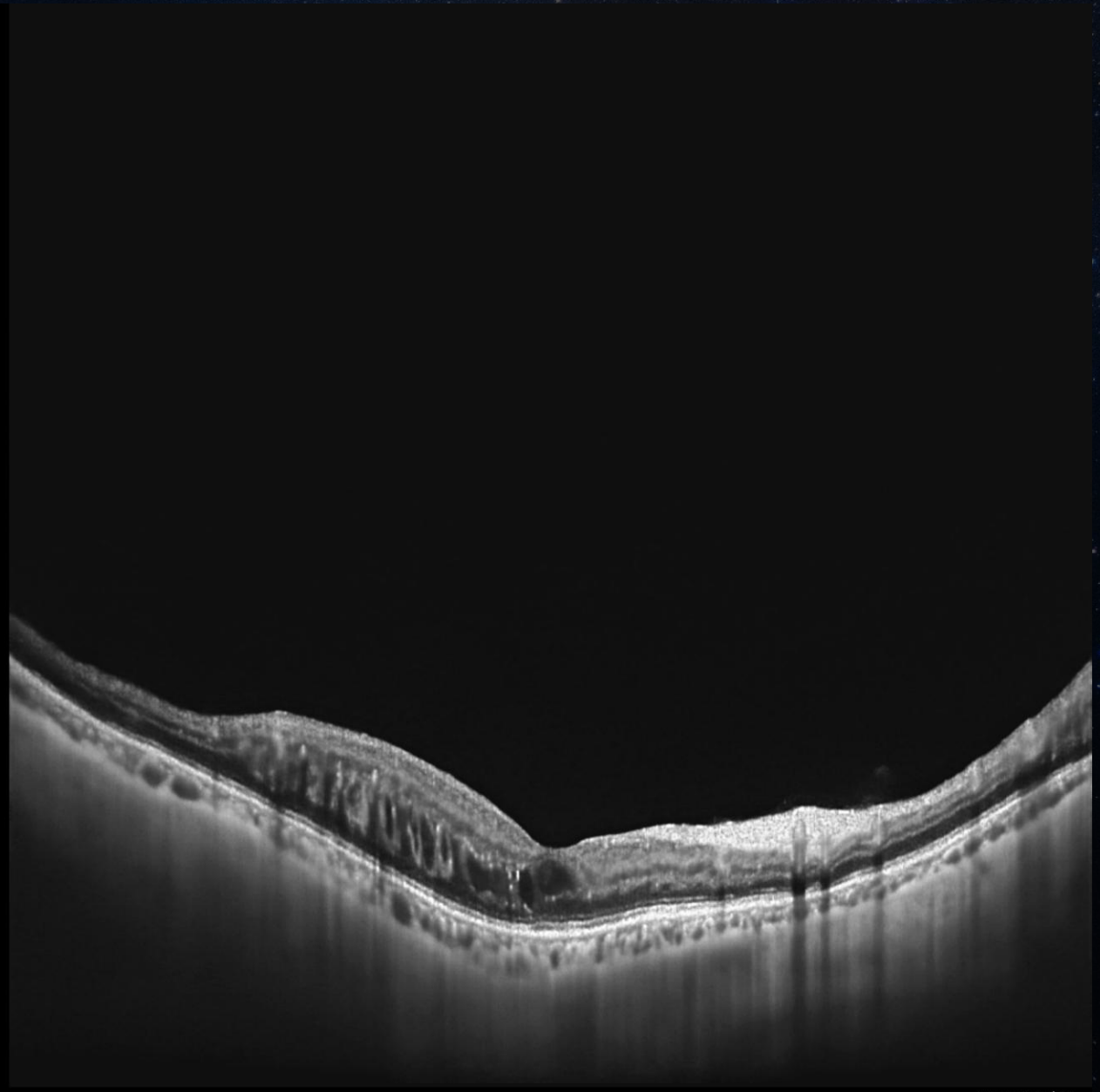
微清医疗
Retina Width: 18.6mm
Img Width: 16.8mm
Img Depth: 6.0mm
FOV: 90°
Average:6/10
Index:8/8
T N

BRVO

程炎

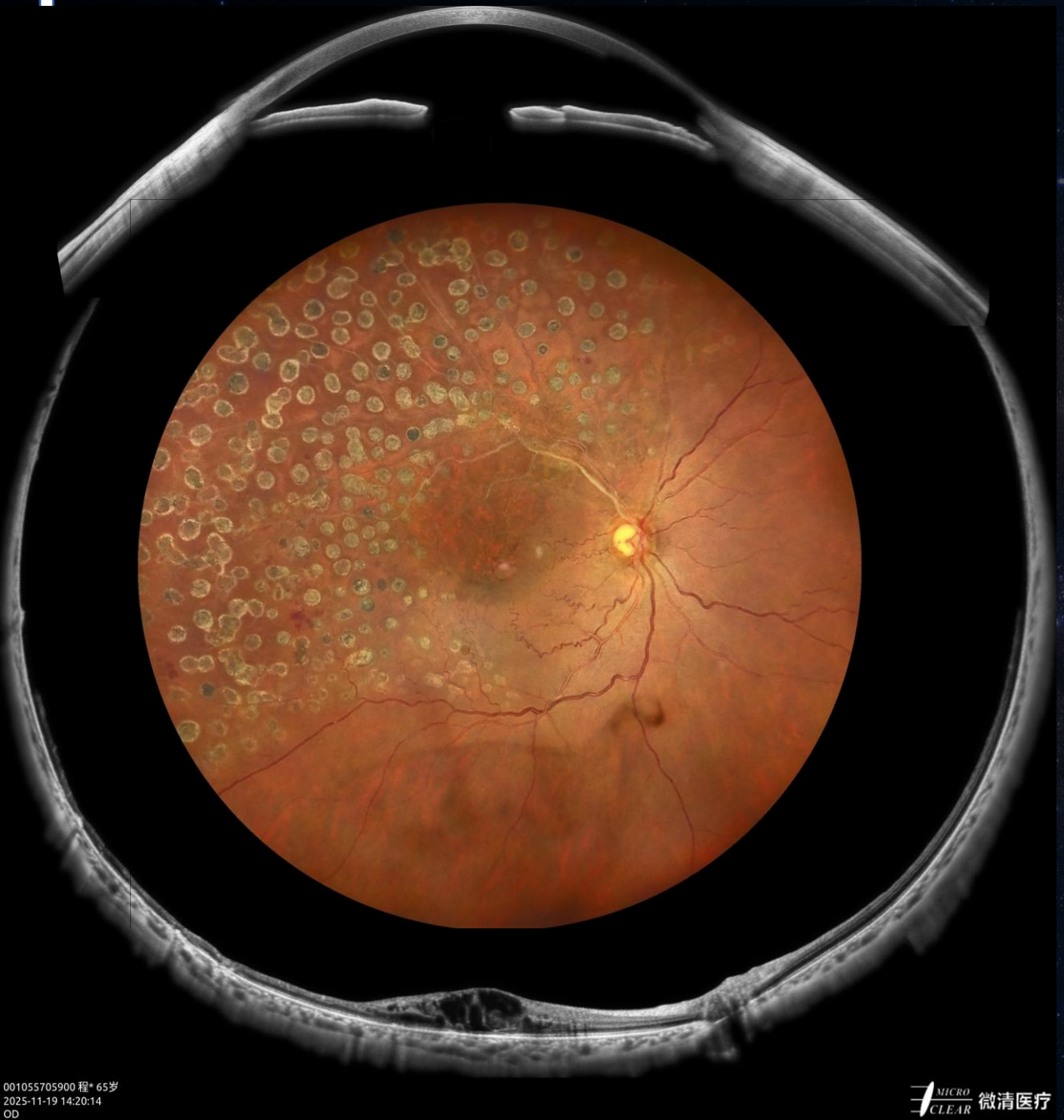
001055705900 程* 65岁
2025-11-19 14:20:14
OD
MICRO CLEAR 微清医疗

001055705900 程* 65岁
2025-11-19 14:18:47
OD Angle 135° COLOR
MICRO CLEAR 微清医疗

BRVO

CVimage:1.26 CV:1.26
Diop:-0.3D

001055705900 程* 65岁
2025-11-19 14:12:24
OD Angle 135° COLOR

Retina Width: 28.0mm
Img Width: 22.0mm

Img Depth: 10.0mm
FOV: 135°

Average:4/4
Index:1/1
T→N

BRVO

柳耀耀

激光术后

BRVO

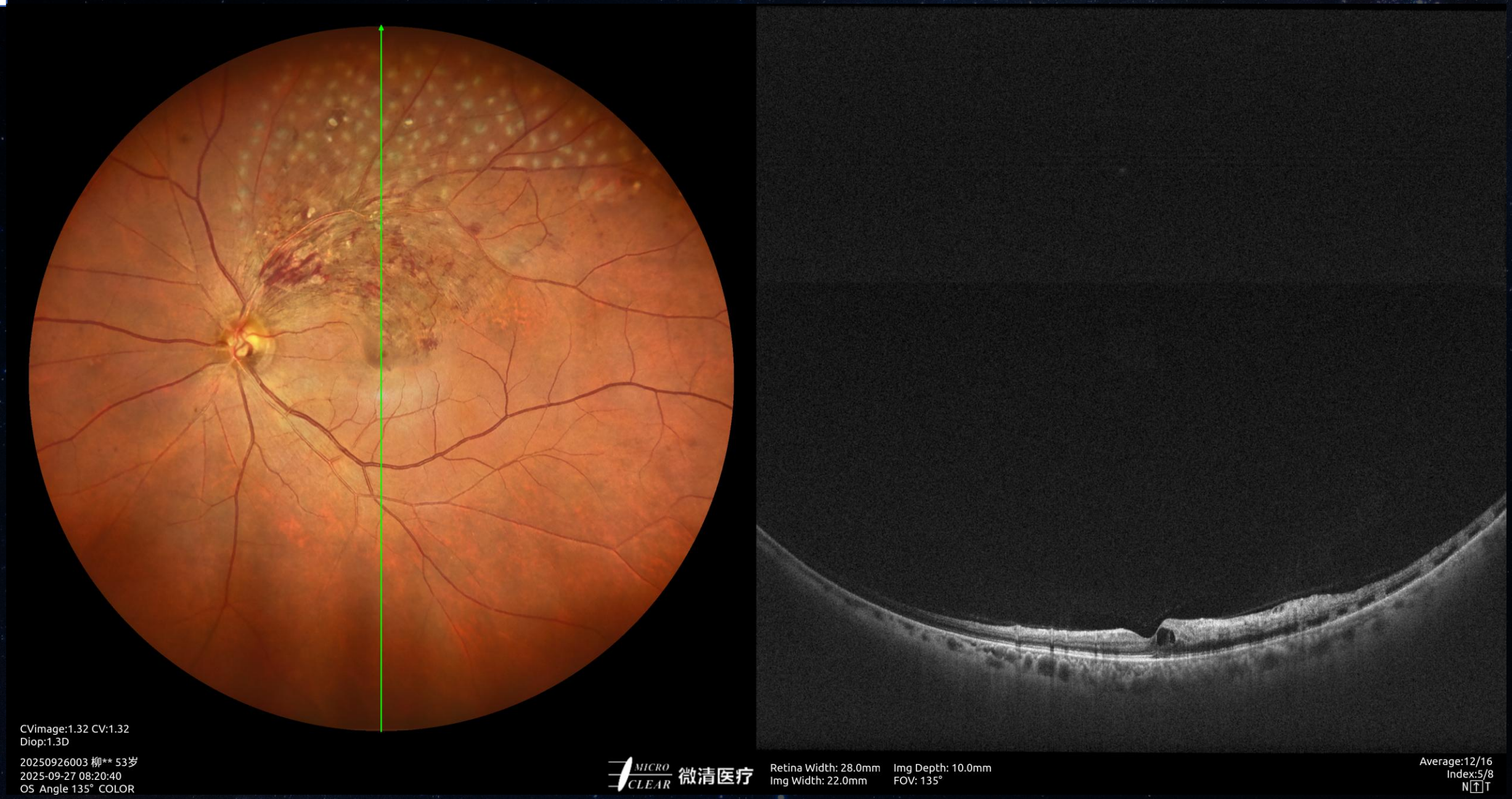
CVimage:1.32 CV:1.32
Diop:1.3D
20250926003 柳** 53岁
2025-09-27 08:20:40
OS Angle 135° COLOR
微清医疗
Retina Width: 28.0mm
Img Width: 22.0mm
Img Depth: 10.0mm
FOV: 135°
Average:12/16
Index:5/8
N T

BRVO

何俊

CVimage:1.07 CV:1.07
Diop:2.8D
2025-10-11 09:55:35
OS Angle 165° COLOR
MICRO CLEAR 微清医疗

2025-10-11 10:08:14
OS Angle 135° FFA (00:40) ART(21)
MICRO CLEAR 微清医疗

BRVO

2025-10-11 09:56:42
OS Angle 45° COLOR

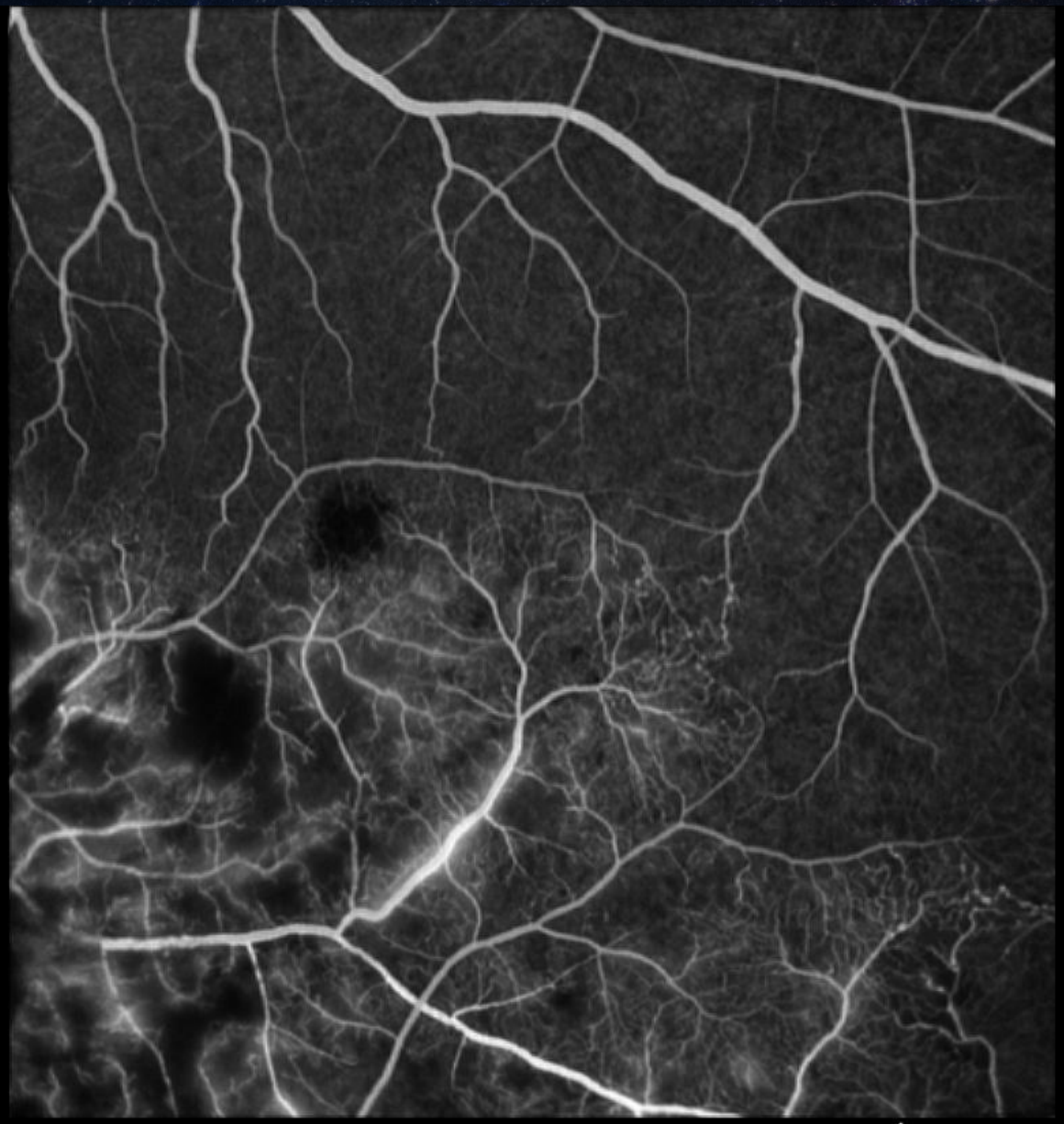

2025-10-11 10:09:47
OS Angle 45° FFA (02:13) ART(10)

wAMD

CVimage:1.59 CV:1.59
Diop:-2.3D,LineScan:1
Rgray:99.7,Ggray:62.8,Bgray:54.6
20251020016 何** 80岁
2025-10-20 16:20:59
OS Angle 135° COLOR
微清医疗

Retina Width: 18.6mm
Img Width: 16.8mm
Img Depth: 10.0mm
FOV: 90°
Average:4/4
Index:8/12
N T

20251020016 何** 80岁
2025-10-20 17:00:33
OS Angle 135° ICGA (25:02) ART(10)
微清医疗

20251020016 何** 80岁
2025-10-20 17:00:33
OS Angle 135° FFA (17:40) ART(10)
微清医疗

wAMD

何银伦

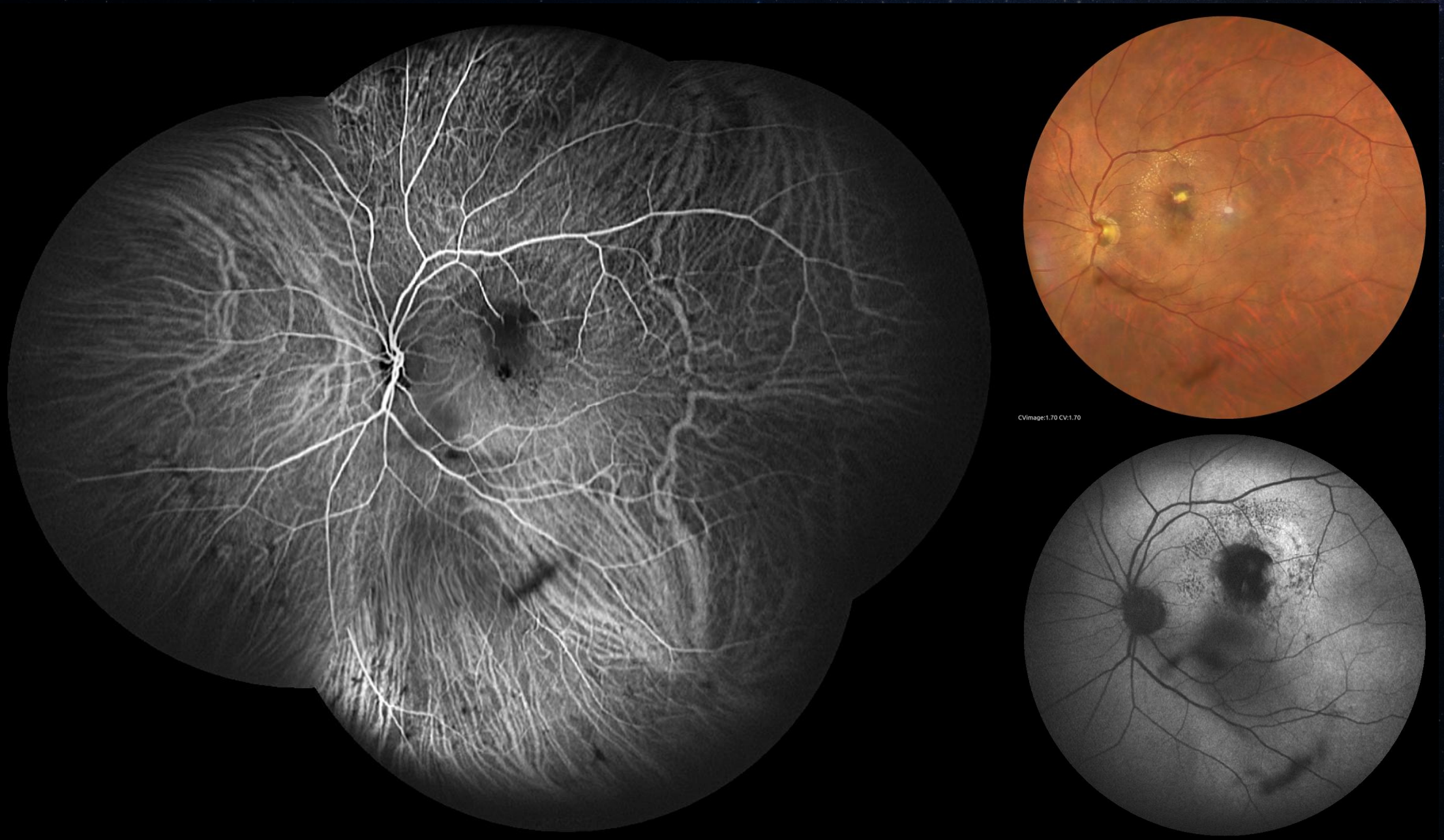

CSC

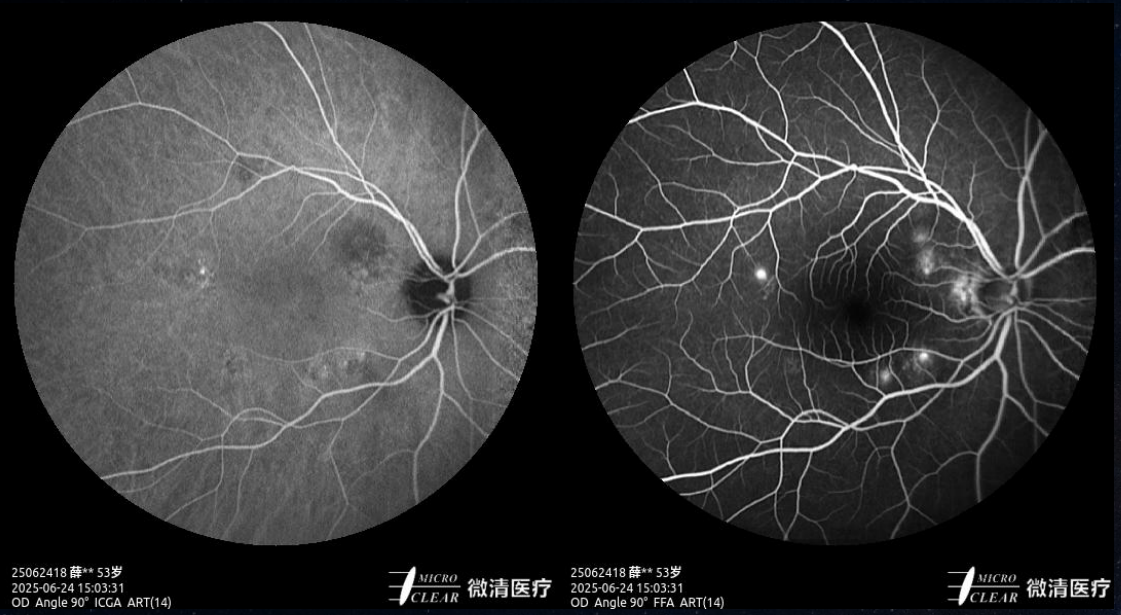
25062418 薛** 53岁
2025-06-24 15:03:31
OD Angle 90° ICGA ART(14)
MICRO CLEAR 微清医疗
25062418 薛** 53岁
2025-06-24 15:03:31
OD Angle 90° FFA ART(14)
MICRO CLEAR 微清医疗

CVimage:1.15 CV:1.15
Diop:0.0D

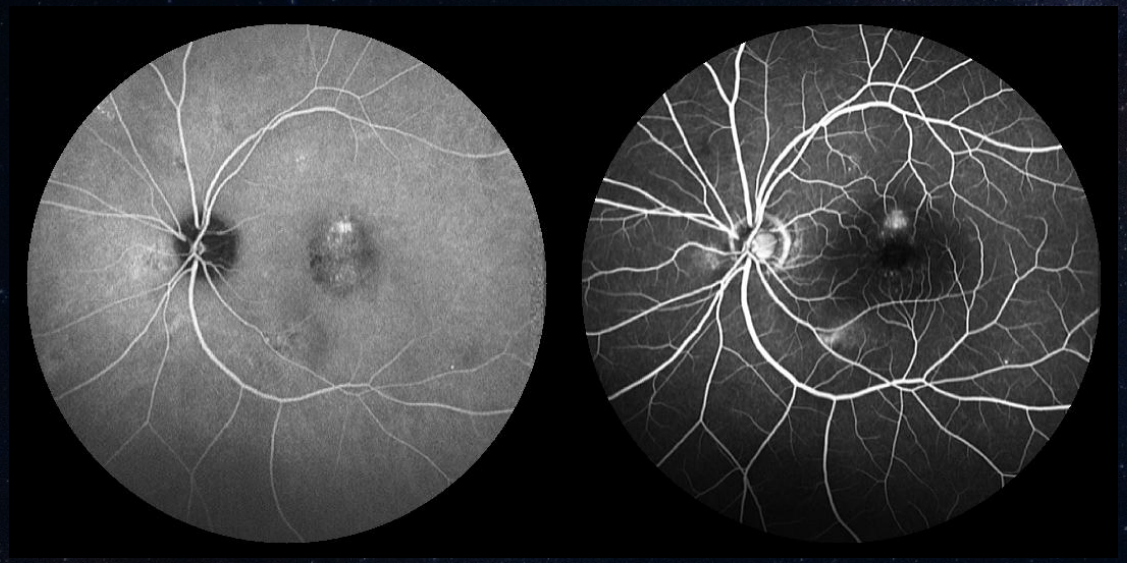

CVimage:1.14 CV:1.14
Diop:0.0D

CSC

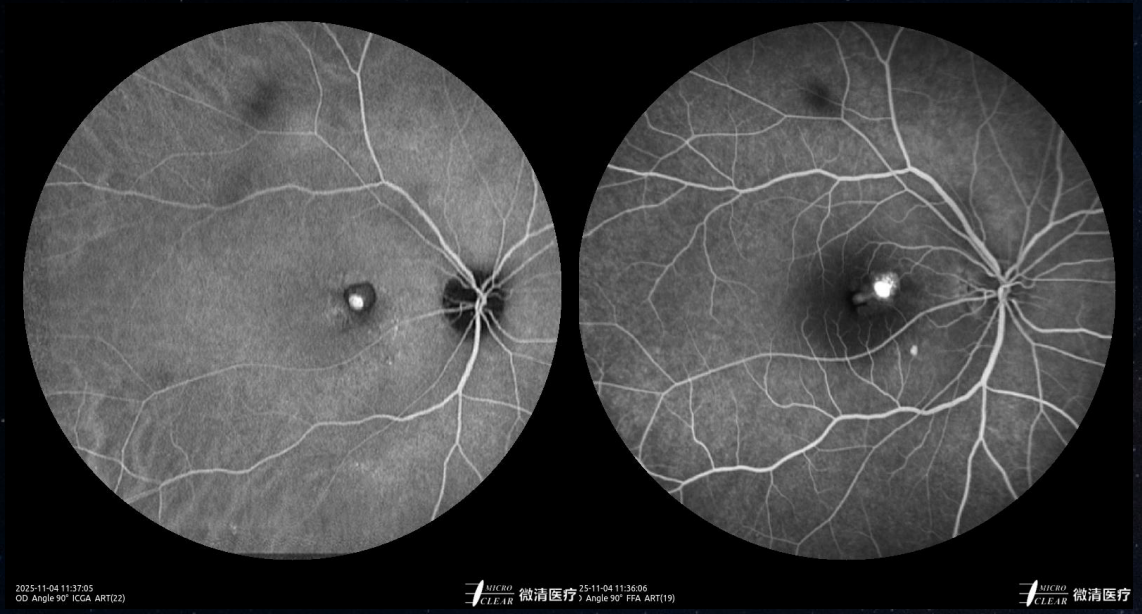
2025-11-04 11:37:05
OD Angle 90° ICGA ART(22)
微清医疗
25-11-04 11:36:06
Angle 90° FFA ART(19)
微清医疗

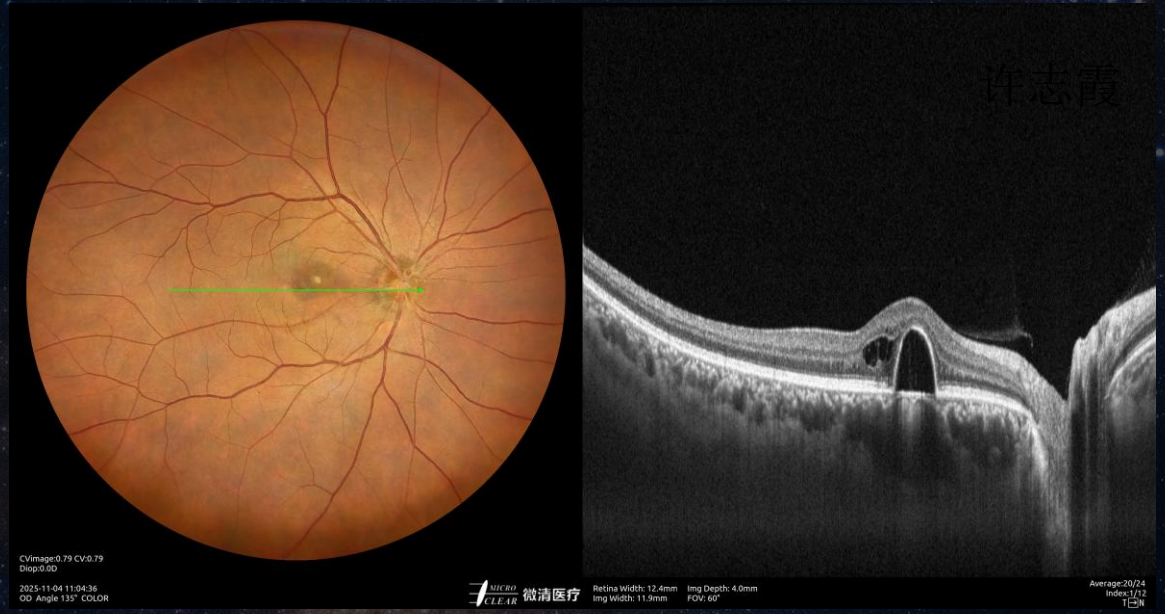
许志霞
CVimage:0.79 CV:0.79
Diop:0.0D
2025-11-04 11:04:36
OD Angle 135° COLOR
微清医疗
Retina Width: 12.4mm
Img Width: 11.9mm
Img Depth: 4.0mm
FOV: 60°
Average:20/24
Index:1/12

BEST Disease

梁瑶

BEST Disease

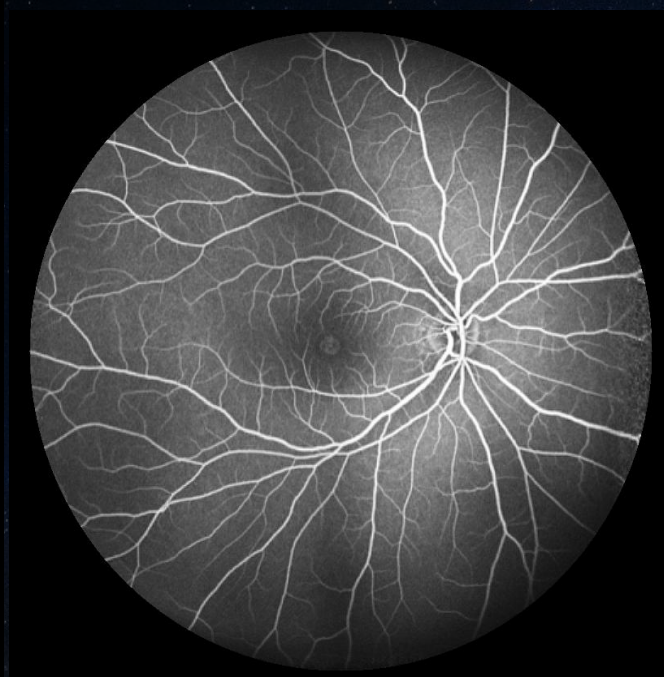

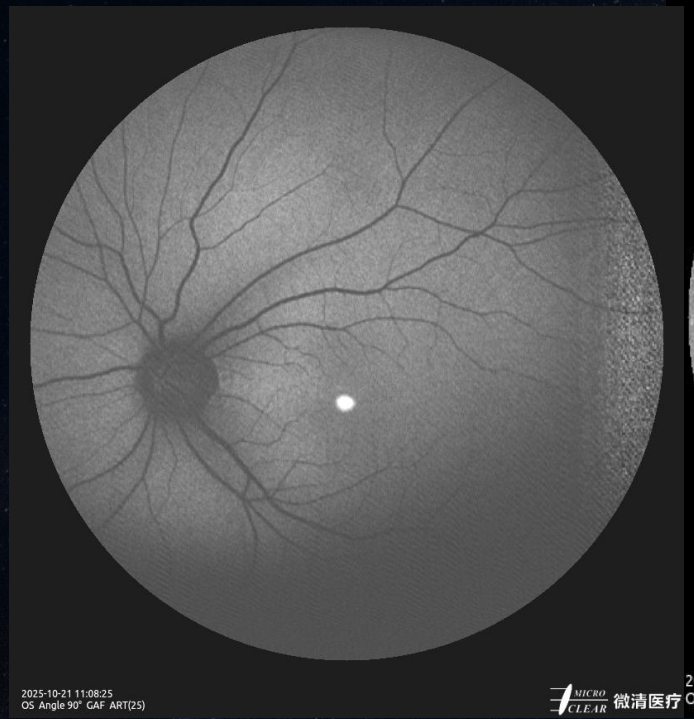

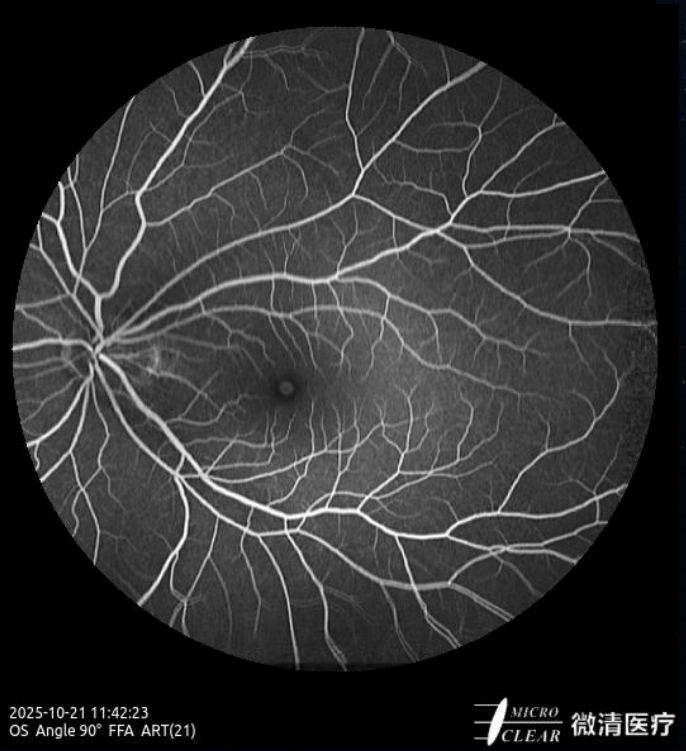

ERM

岳玉霞

CVimage:1.29 CV:1.29
Diop:3.0D
0026143828 岳** 61岁
Retina Width: 12.4mm
Img Width: 11.9mm
Img Depth: 4.0mm
FOV: 60°
Average:26/26
Index:1/8
N⇄T
0026143828 岳** 61岁
Average:22/26

CNV

杨秋香

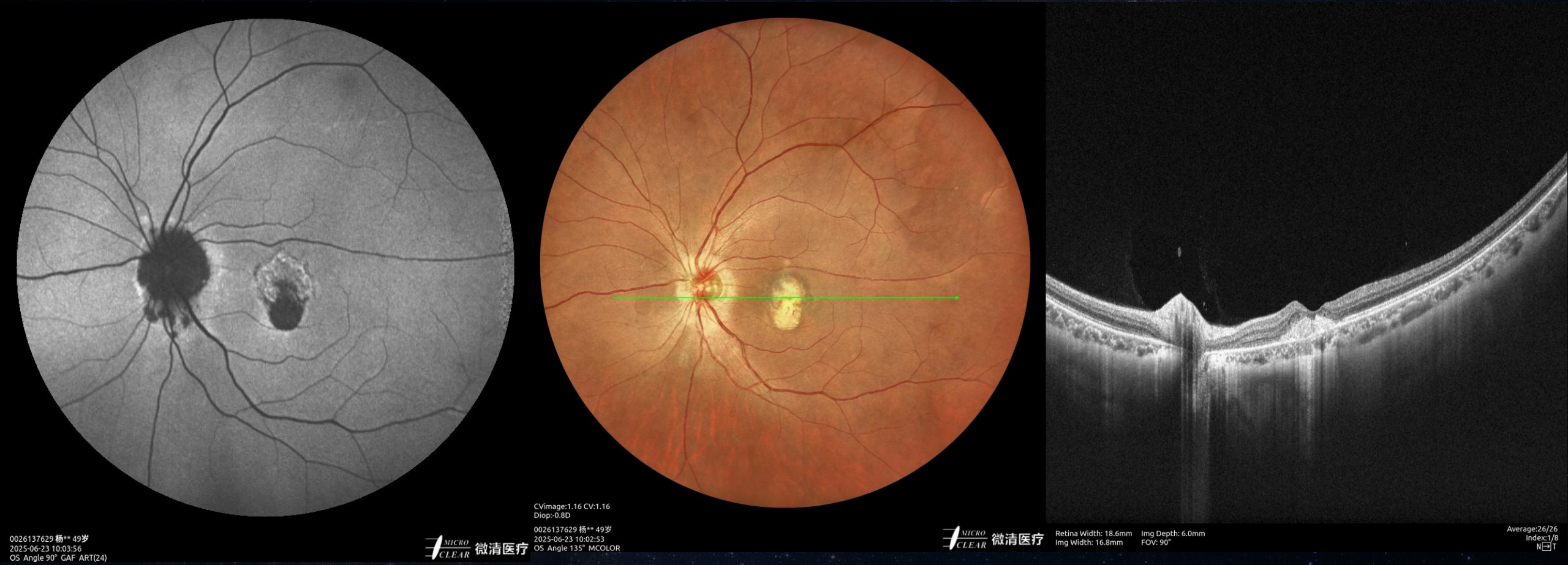
0026137629 杨** 49岁
2025-06-23 10:03:56
OS Angle 90° GAF ART(24)
微清医疗
CVimage:1.16 CV:1.16
Diop:-0.8D
0026137629 杨** 49岁
2025-06-23 10:02:53
OS Angle 135° MCOLOR
微清医疗
Retina Width: 18.6mm
Img Width: 16.8mm
Img Depth: 6.0mm
FOV: 90°
Average:26/26
Index:1/8
N T

CNV

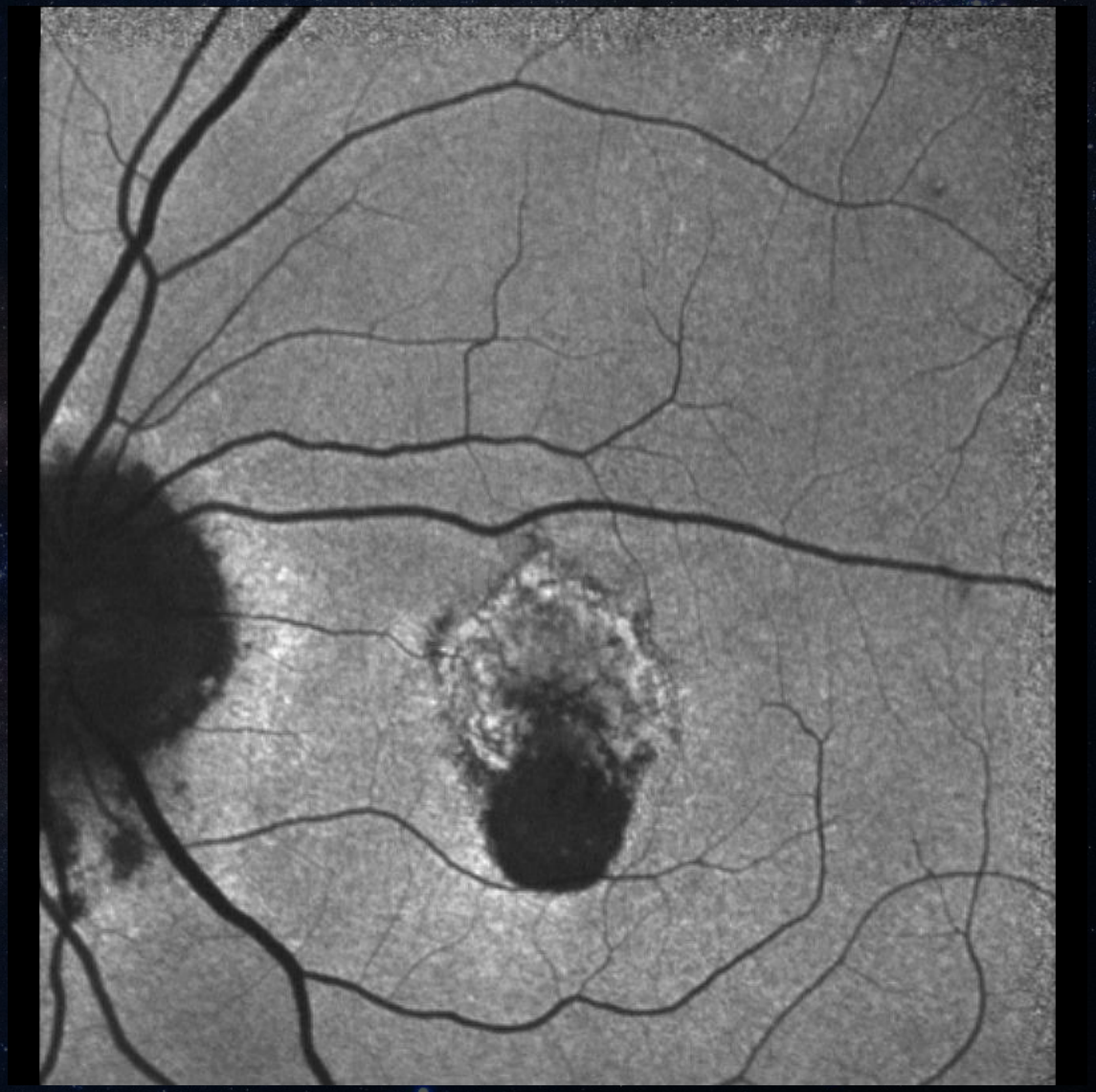

COATS

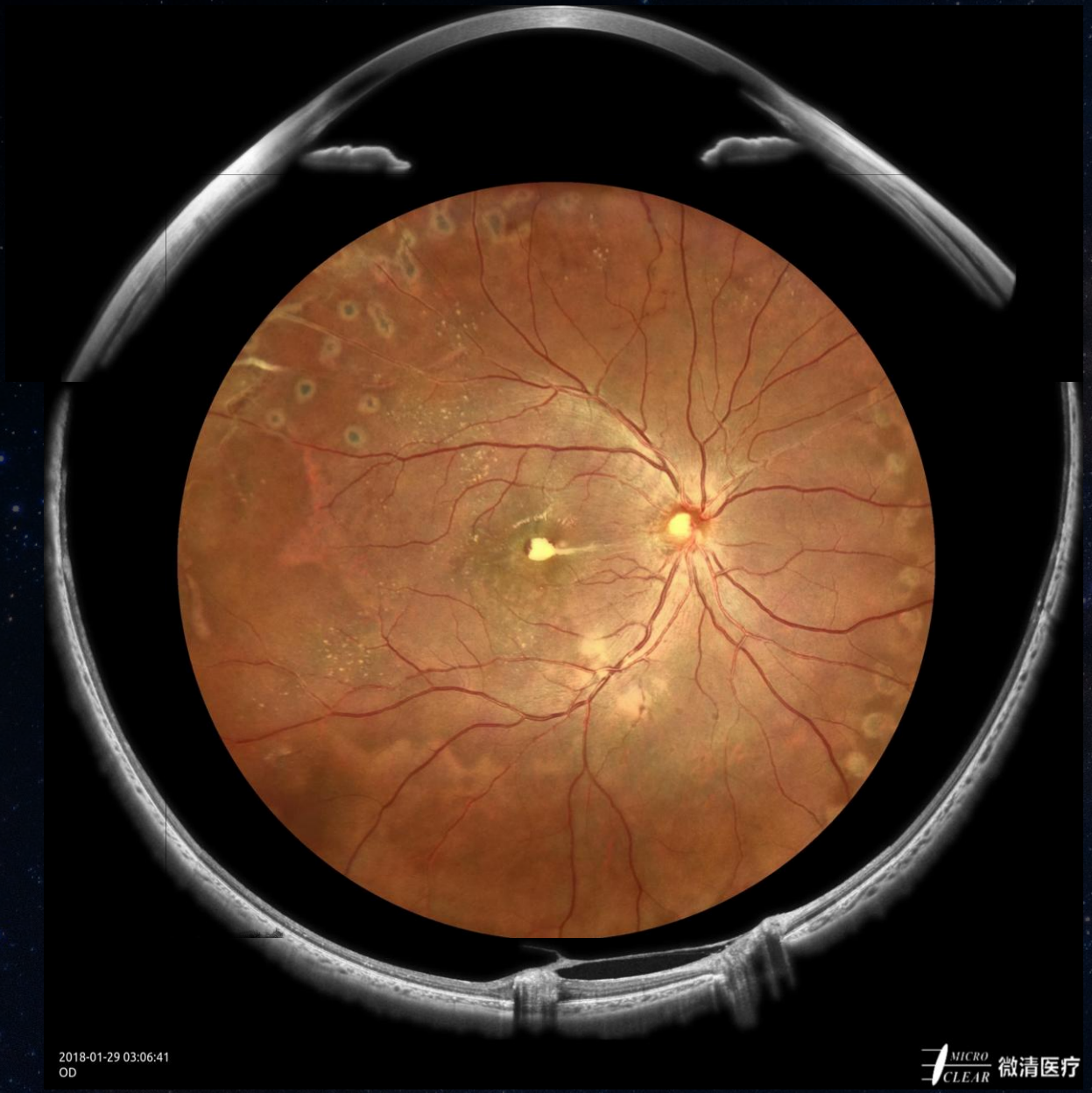

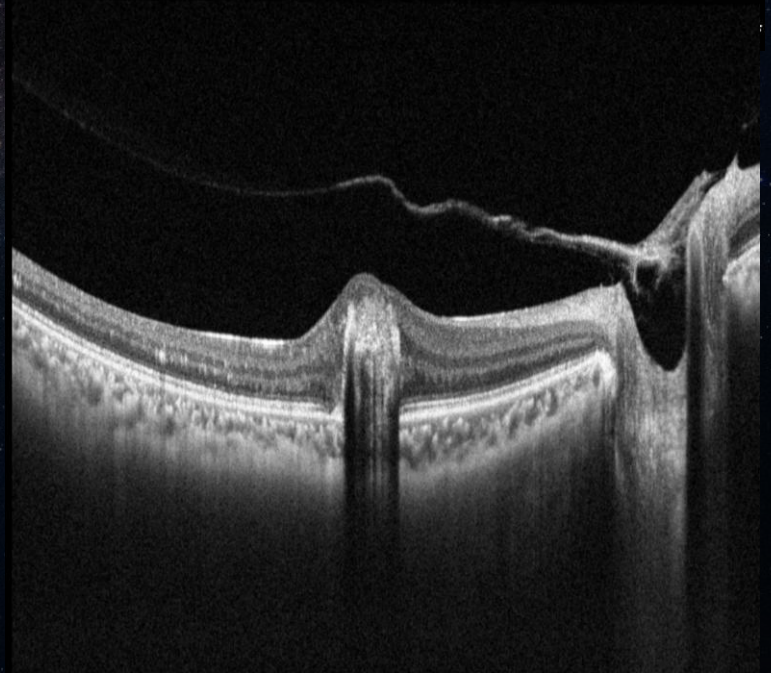

MICRO CLEAR SKY

李俊熙

Vitreomacular Traction （VMT）

李桂芬

Vitreomacular Traction （VMT）

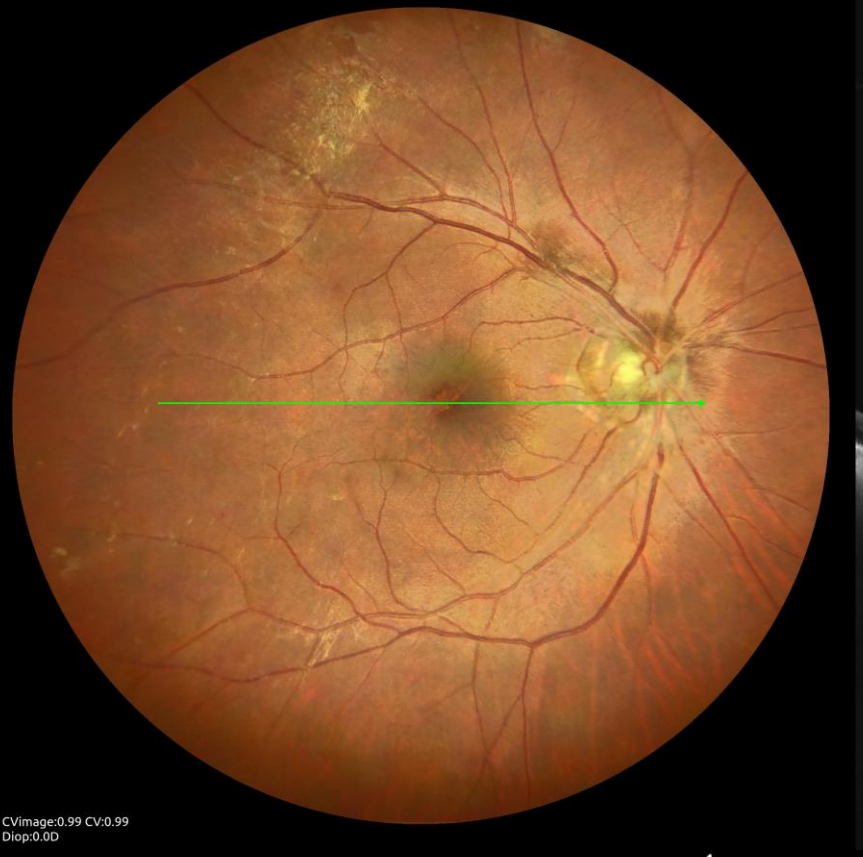

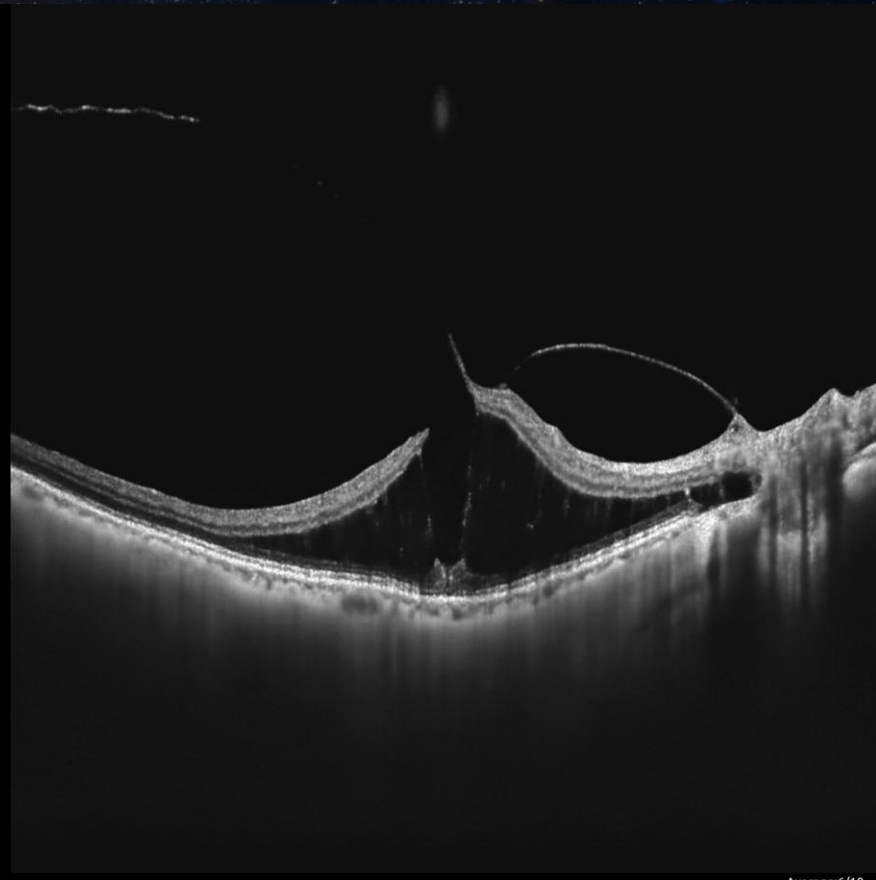

Optic Neuropathy

Acute regional occult outer retinopathy

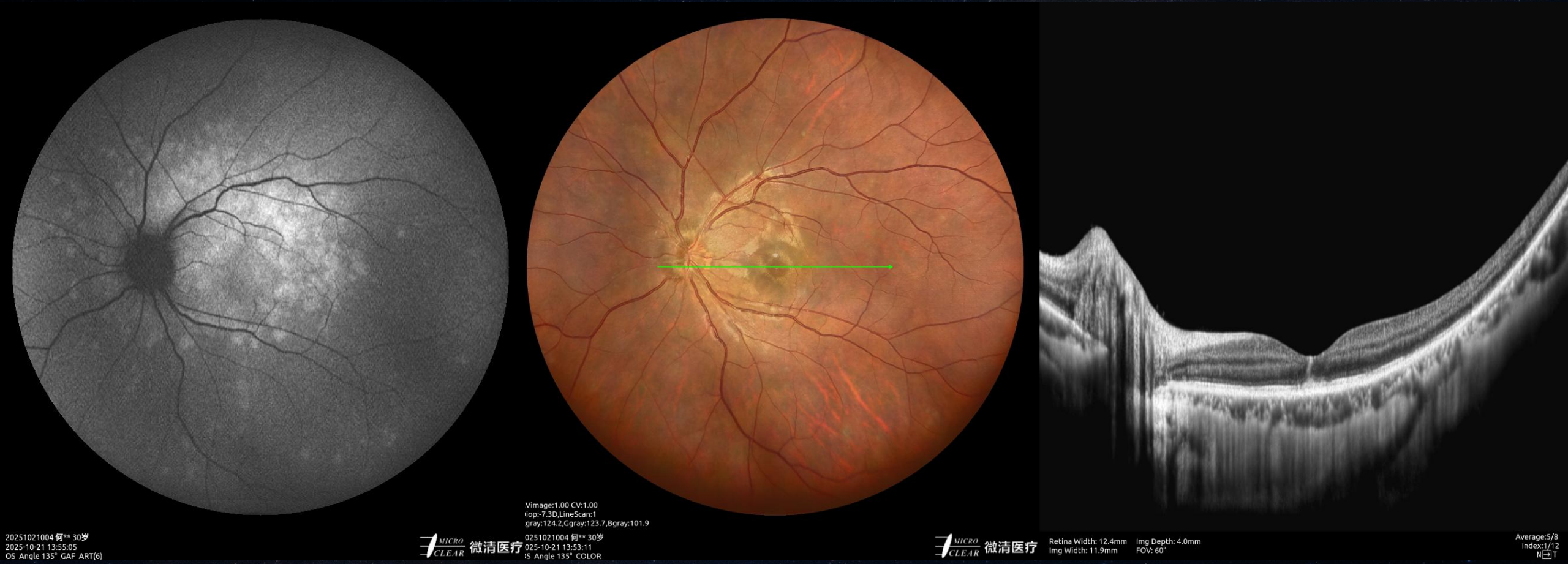

Retinal Vasculitis

钱晓辉



Retinal Vasculitis

CVimage:1.10 CV:1.10
Diop:0.0D

0026000043 钱** 61岁
2025-06-20 09:00:45
OD Angle 135° MCOLOR

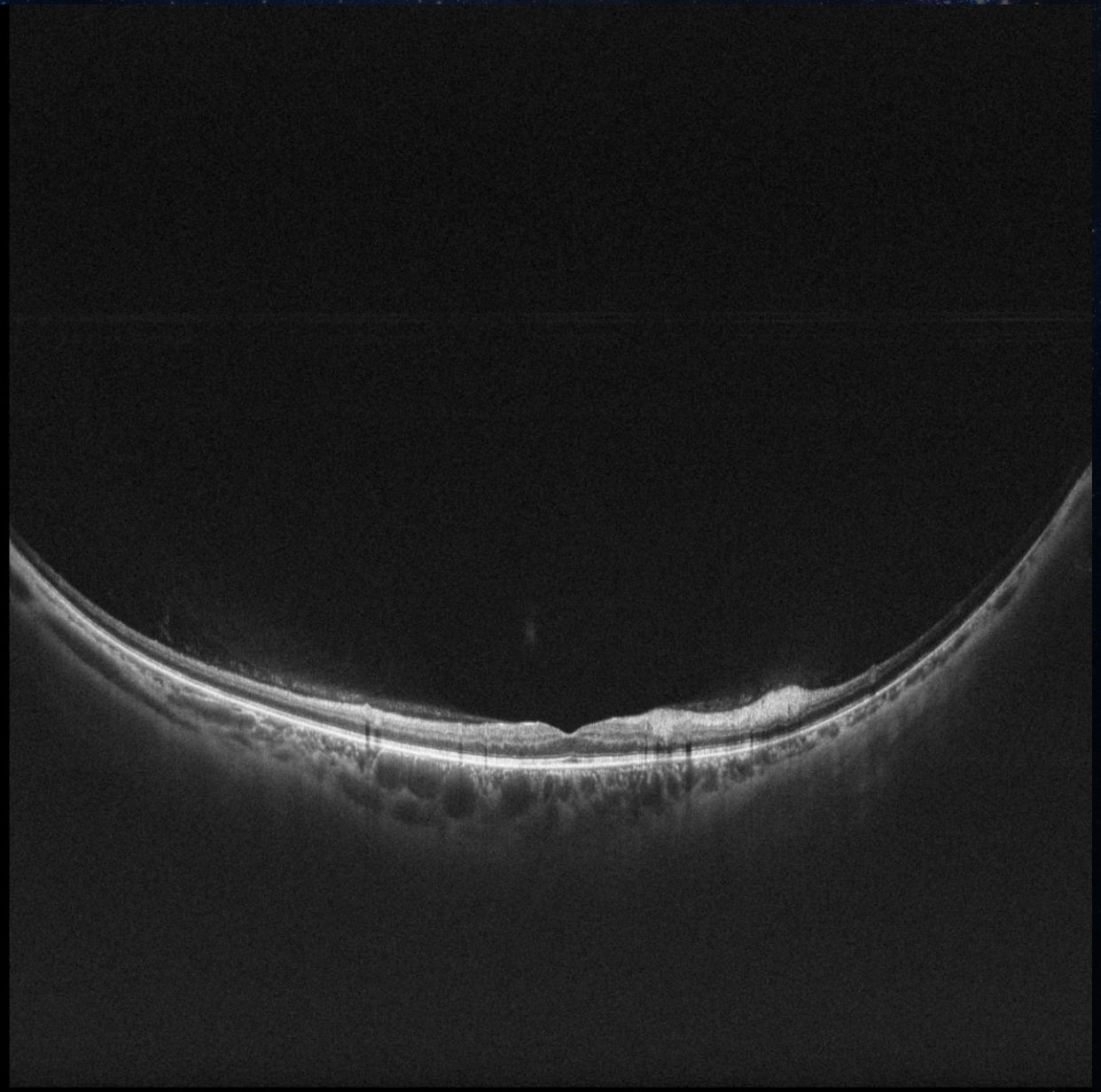

Retina Width: 28.0mm
Img Width: 22.0mm

Img Depth: 10.0mm
FOV: 135°

Average:26/26
Index:7/8
T↘N

Peripheral Retinal Degeneration

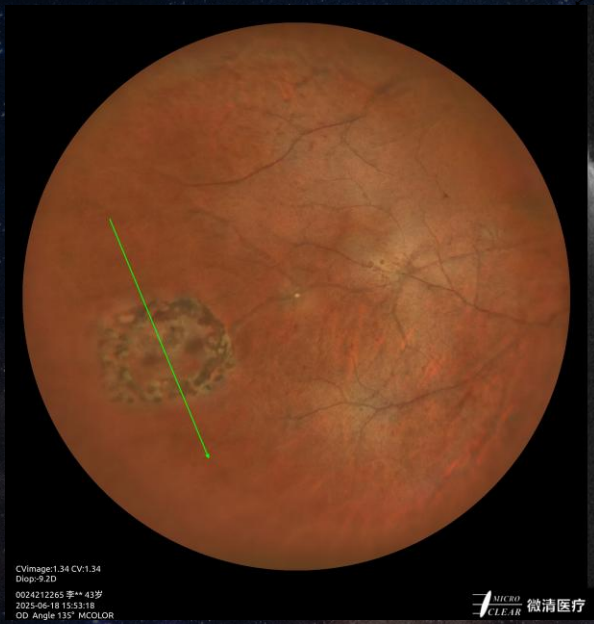

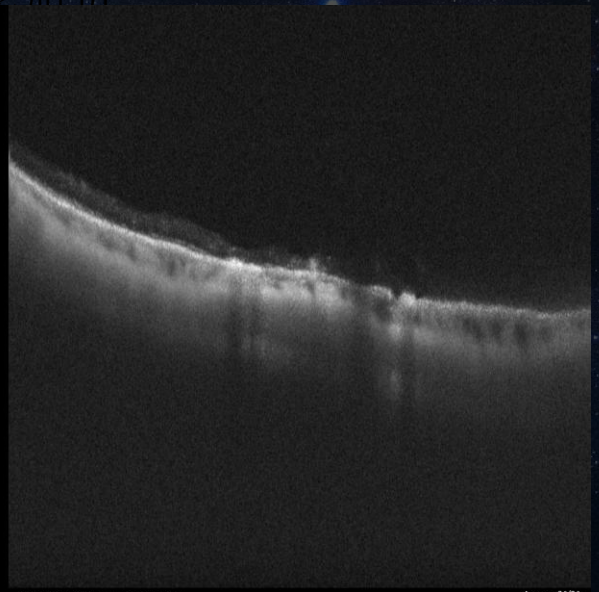

Retinal Angioma

陈俊平

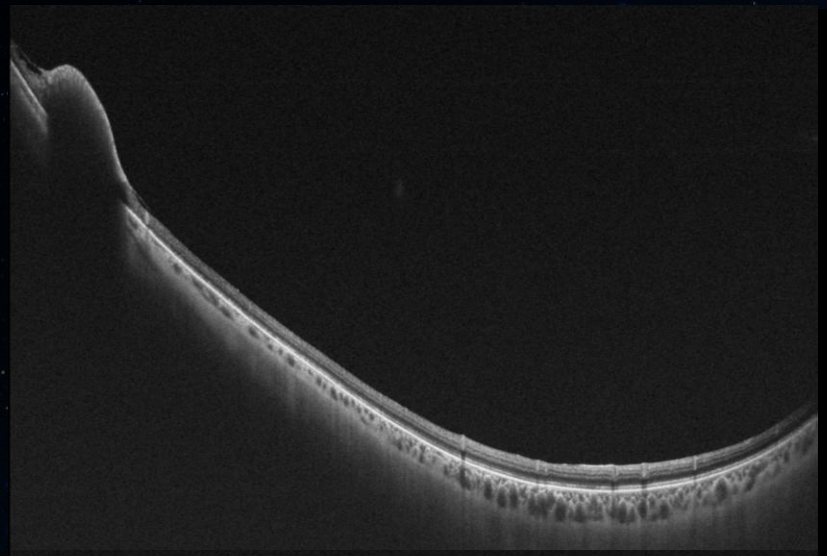

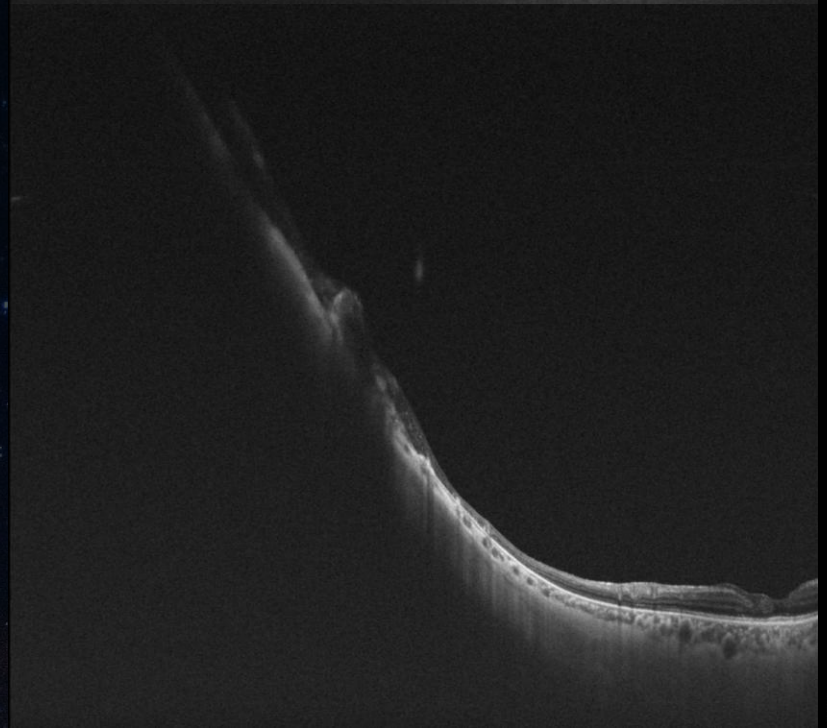

Choroidal melanoma (postoperative)

张春节

MICRO CLEAR SKY

Choroidal melanoma (postoperative)

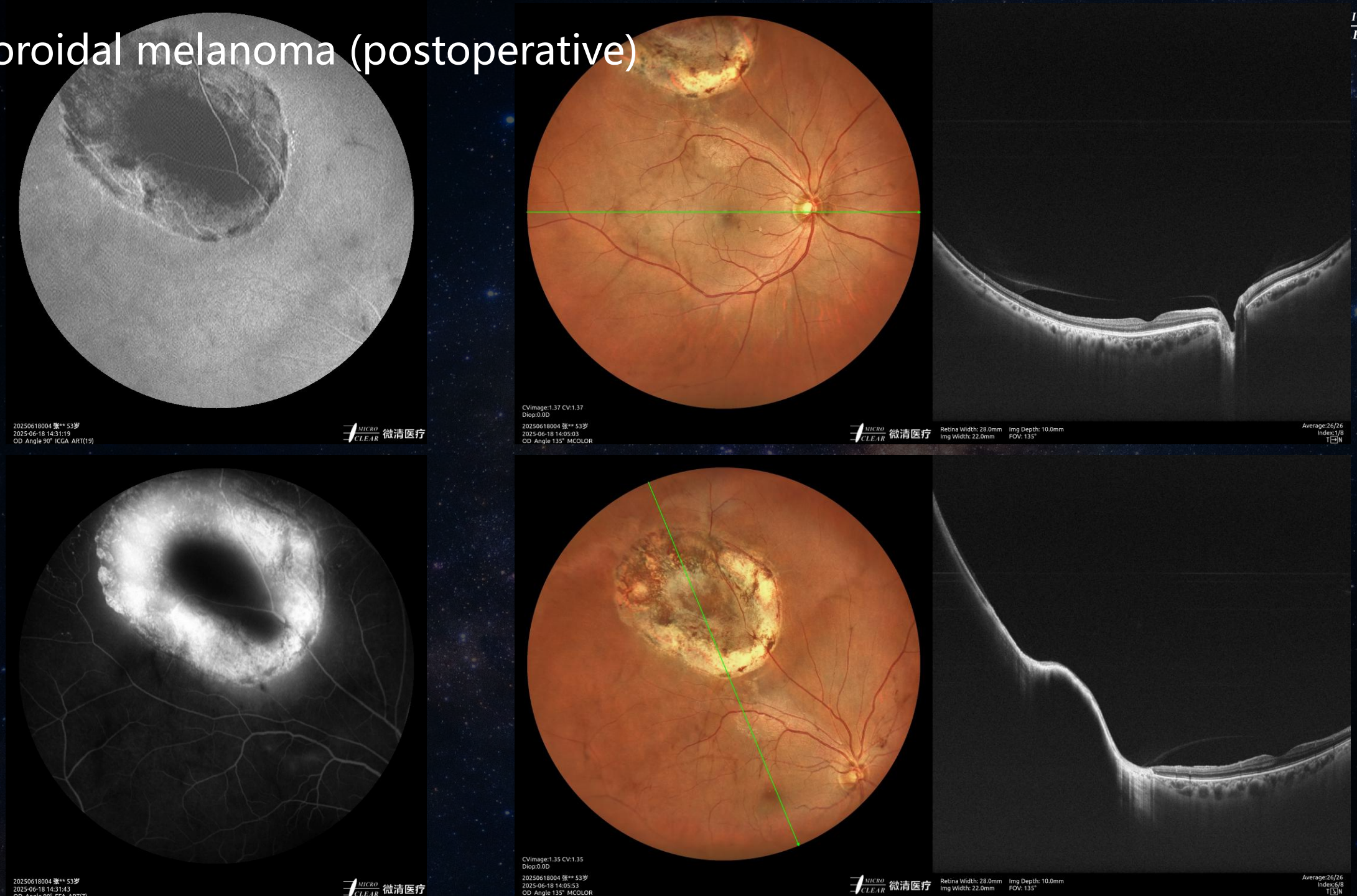

SIR oftalmica

DISTRIBUTING EXCELLENCE SINCE 1989

SIR OFTALMICA SPA

VIA NAPOLEONA 7

22100 – COMO

ITALY

TEL. +39.031.570869

E-MAIL: INFO@SIROFTALMICA.COM

WWW.SIROFTALMICA.COM